

See discussions, stats, and author profiles for this publication at: <https://www.researchgate.net/publication/237458873>

Analysis of causes that led to baby Ron James Douglas' cardiopulmonary arrest, bleeding (intracranial, retinal, and pulmonary), and rib fracture

Article

CITATION

1

READS

40

1 author:



Mohammed Al-Bayati

Toxi-Health International

50 PUBLICATIONS 480 CITATIONS

SEE PROFILE

Analysis of causes that led to baby Ron James Douglas' cardiopulmonary arrest, bleeding (intracranial, retinal, and pulmonary), and rib fracture

Mohammed Ali Al-Bayati, Ph.D., DABT, DABVT

Toxicologist & Pathologist

Toxi-Health International

150 Bloom Drive, Dixon, CA 95620

Phone: +1 707 678 4484 Fax: +1 707 678 8505

Email: maalbayati@toxi-health.com

Abstract

Ron James Douglas was 16 weeks old when he choked after being fed and suffered from cardiopulmonary arrest. The paramedics resuscitated him and took him to a hospital. He was pronounced dead at about 25 hours following admission. An autopsy was performed and the medical examiner (ME) found subdural, subarachnoid, and retinal bleeding and an acute rib fracture of the left anterolateral 6th rib. The ME alleged that Ron's death was caused by blunt trauma to the head and trunk. Ron's father was accused of killing his son.

My investigation reveals that Ron had a serum calcium level of 6.2 mg/dL and suffered from a severe hypocalcemia. Hypocalcaemia in children has caused seizures, respiratory disorders, laryngospasm, and/or severe cardiac disorders which resulted in sudden death. Hypocalcemia is the likely cause of Ron's choking and cardiopulmonary arrest. Ron was born 11 weeks premature and developed hyperphosphatemia at 39 days following birth. The likely causes of Ron's hypocalcemia are hypoparathyroidism and hyperphosphatemia. He also developed hemolytic anemia and his thymus was involuted. His hemoglobin level and hematocrit value were 6.2 g/dL and 19.4%, respectively.

Ron's intracranial bleeding developed following admission to the hospital and the likely causes of his bleeding are acute liver injury, treatment with epinephrine, and disseminated intravascular coagulation (DIC). In addition, severe anemia contributed to his retinal bleeding. Cardiopulmonary resuscitation is the likely cause of Ron's rib fracture. The clinical and the medical studies described in this report do not support the ME's allegation that Ron was killed by blunt trauma.

© Copyright 2009, Medical Veritas International, Inc. All rights reserved.

Keywords: blunt trauma; brain edema; cardiopulmonary resuscitation; cardiopulmonary arrest; disseminated intravascular coagulation; hypocalcemia; hyperphosphatemia; jaundice; involuted thymus; premature infant; pulmonary bleeding; respiratory distress syndrome; retinal bleeding; rib fracture; subdural bleeding; subarachnoid bleeding;

1. Summary of the case and findings

Ron James Douglas suffered from cardiopulmonary arrest on the morning of March 10, 2007. He was 16 weeks old. His father called 911 and the paramedics performed cardiopulmonary resuscitation (CPR) on Ron and gave him 0.3 mL of epinephrine (IV). CareFlight took Ron to Renown Regional Medical Center (RRMC) for evaluation.

Ron was admitted to the hospital at 0806 on March 10, 2007 and pronounced dead at 1042 on March 11th. Dr. Katherine P. Raven performed the autopsy on Ron's body on March 12th. She found subdural, subarachnoid, and retinal bleeding and acute rib fracture of the left anterolateral 6th rib.

Raven alleged that Ron's death was caused by blunt trauma to the head and trunk. Ron's father was accused of killing his son and arrested. The father's defense attorney, Mr. David R. Houston (Reno, Nevada) requested that I evaluate the medical evidence in Ron's case, to find the likely causes that led to Ron's illness, bleeding, and death.

I am a toxicologist and pathologist with over 20 years experience in these fields. I have evaluated many cases of children who died suddenly from unexplained causes and cases of children and adults who suffered from acute and/or chronic illnesses. I was able to explain the causes of illnesses and death in these cases using differential diagnosis. I have also served as an expert witness in many medical-legal cases involving children and adults. I have published over 45 articles in medical and scientific journals.

I evaluated Ron's medical records, autopsy report, testimonies of witnesses, police reports, and the medical articles cited in this report using differential diagnosis. I also examined the H & E stained tissue sections of organs and tissues taken at autopsy microscopically. Approximately 300 hours were required to evaluate the medical evidence, perform an analysis, and write this report. My investigation in this case reveals the following:

1) Ron was born 11 weeks premature on November 17, 2006. His weight was 1.287 kg. His length and head circumference were 36.5 cm and 27.5 cm, respectively. His mother received corticosteroids prior to delivery. The complications during labor were chorioamnionitis and premature rupture of the membranes. The amniotic fluid was foul smelling. The mother tested positive for Group B Streptococcus positive and was treated with ampicillin (Section 2).

2) Ron was admitted to the neonatal intensive care unit immediately following birth and was discharged on 1/10/2007. During his 54 days hospitalization, Ron developed hemolytic anemia, jaundice, respiratory distress syndrome, apnea, gastroesophageal reflux disease (GERD), and hyperphosphatemia.

A blood analysis performed following birth on November 17, 2006 showed Ron had red blood cell count (RBC), hematocrit (HCT) value, and hemoglobin (HG) level higher than the normal range. However, Ron's RBC, HCT, and HG levels declined gradually and he developed anemia. His hematocrit value reduced from 54.1% to 28.3% within 52 days.

Ron developed hyperbilirubinemia on November 18, 2006 and was treated with phototherapy. However, his serum bilirubin level reached a peak of 9.9 mg/dL on December 18, 2006. In addition, Ron developed hyperphosphatemia at 39 days following birth. He had a blood phosphate level of 8.4 mg/dL. Ron was discharged from the hospital on January 10, 2007.

3) Ron choked after feeding and suffered from cardiopulmonary arrest on March 10th. A blood analysis performed at 40 minutes following Ron's admission to the hospital (FAH) revealed that he was suffering from a severe hypocalcemia. He had a serum calcium level of 6.2 mg/dL. Hypocalcemia is defined as total blood calcium level below 9.0 mg/dL.

Individuals suffer from hypocalcemia usually develop laryngeal spasm, convulsion, seizure, and/or cardiac arrest. For example, Mallet stated that the clinical manifestations of hypocalcemia in children are neurological disorders such as seizures, respiratory disorders with possible laryngospasm, and/or severe cardiac disorders that may result in sudden death. Hypocalcemia is the likely cause of Ron's laryngeal spasm and his cardiopulmonary arrest.

The likely causes of Ron's hypocalcemia were hypoparathyroidism and hyperphosphatemia. Ron developed hyperphosphatemia at 39 days following birth. However, his blood phosphate level was not measured during the period between December 27, 2006 and March 11, 2007. In addition, the functions of his parathyroid glands were not assessed (Section 7).

4) The increased level of phosphate in Ron's blood and tissues led to the binding of phosphate with calcium and the deposition of calcium phosphate in liver and kidneys, causing injuries to these organs. A blood analysis performed at about 3 hours FAH revealed that Ron had elevated levels of alkaline phosphatase, SGOT, and SGPT enzymes in serum. A urine analysis performed at 2 hours FAH revealed that Ron's urine contained significant amount of protein, blood, red blood cell, and white blood cells (Section 7).

5) A blood analysis performed on March 10th showed that Ron was suffering from a severe anemia. Ron's red blood cell count, hematocrit value and hemoglobin level were about 50% of normal at 40 minutes FAH. Clinical data and biomarkers indicate that Ron was suffering from hemolytic anemia and his problem developed following birth. However, he was not monitored following his release from the hospital on January 10, 2007 to detect the problem (Section 8).

6) Ron's intracranial bleeding developed following his admission to the hospital on March 10th. Ron's bleeding was not limited to the head region. He also had pulmonary bleeding and subdural and epidural bleeding over the cauda equina of the spinal cord. The bleeding in Ron's lungs was not reported by the medical examiner (Figures 1, 2, 3).

The likely causes of Ron's bleeding were acute liver injury, treatment with high dose of epinephrine, and disseminated intravascular coagulation (DIC). In addition, Ron was suffering from a severe anemia and retinal bleeding has been reported in individuals suffering from severe anemia (Section 10).

Ron's prothrombin time (PT), activated partial thromboplastin time (APTT) and international normalized ratio (INR) values were elevated at 3 hour FAH. His PT was 161% of the upper normal level. In addition, Ron's platelet count at 40 minutes FAH was $220 \times 10^3/\mu\text{L}$ and increased by 156% as a result of the blood transfusions received. However, his platelet count reduced by 52% within 11 hours due to DIC (Section 10).

7) The likely causes of Ron's brain edema were anoxia, acidosis, treatment with high doses of sodium bicarbonate, and irritation from bleeding. Most of his brain edema developed after his admission to the hospital on March 10th. Anoxia, ischemia, treatment with high doses of sodium bicarbonate, and the increase in the intracranial pressure caused the ischemic changes and necrosis observed in Ron's brain (Section 11).

For example, Dolinak *et al.* evaluated the relationship between hypoxia and the incidence of axonal injury in the brains of individuals died from cardio-respiratory arrest (17 cases) and status epilepticus (12 cases). Axonal damage was seen in 9/17 and 7/12 of the cases with cardiac arrest and status epilepticus, respectively, in most of whom there was also evidence of raised intracranial pressure (Section 11).

8) The likely cause of Ron's acute fracture of the left anterolateral 6th rib was CPR performed on March 10th. Ron received chest compressions prior to the arrival of the paramedics and then the paramedics performed CPR. Single and multiple rib fractures have been observed in infants who received CPR following cardiac arrest.

For example, Dolinak evaluated the occurrence of CPR-related rib fractures in 70 infants with no history or indications of injury. At autopsy, subtle fractures of the anterolateral aspects of the ribs were discovered in 8 (11%) of the 70 cases. In 7 of the 8 cases, multiple ribs were fractured (ranging up to 10 rib fractures), and in 5 of these cases, the rib fractures were bilateral (Section 12).

9) Ron's thymus was involuted and replaced by fat. Ron had several risk factors that are known to cause reduction in thymus size and involution. These include premature birth, chorioamnionitis, infections, and the treatment with corticosteroids. For example, Yinon *et al.* evaluated twenty-one pregnant women between 24 and 35 weeks of gestation with preterm premature rupture of membranes (PROM). Serial ultrasound examinations were performed during the latency period, and measurements of the fetal thymus size were obtained. Small thymus was defined as a thymus perimeter $< \text{or} = 5^{\text{th}}$ percentile.

Diagnosis of chorioamnionitis was made using neonatal clinical parameters and histological examinations of the placentas. They found that 13 infants presented with thymus size below the 5th percentile. Among the 13 infants with small thymus, nine (69%) had clinical or histological findings consistent with the diagnosis of chorioamnionitis (Section 9).

10) Raven's allegations that Ron was a healthy baby prior to his cardiopulmonary arrest on March 10th and was killed by blunt trauma to the head and trunk are not supported by the clinical and the medical studies described in this report.

2. Ron's birth event and his condition following birth

Ron James Douglas was born via vaginal delivery at the Renown Regional Medical Center, Reno, Nevada. He was born about 11 weeks premature at 1201 on November 17, 2006. Estimated gestation was 28 weeks and 5 days. His mother was given nifedipine to suppress premature labor. She also received corticosteroids.

The complications during labor were chorioamnionitis and premature rupture of the membranes. The amniotic fluid was foul smelling. The mother tested positive for Group B Streptococcus and was treated with ampicillin. She was also given pitocin during labor and delivery.

At delivery, the baby was cyanotic and had bradycardia. His Apgar score was 6 and 8 at 1 and 5 minutes, respectively. Treatment received at delivery included oral suctioning, emergency intubation, positive pressure ventilation, oxygen, and stimulation. He also received Hepatitis B vaccine and 0.5 mg of vitamin K (IM).

Ron's weight was 1.287 kg. His length and head circumference were 36.5 cm and 27.5 cm, respectively. The baby and his mother have O positive blood type and the baby was Coombs negative. The mother's syphilis screen was non-reactive. Her Hepatitis and HIV screens were negative. Her Rubella screen indicates that she was immune [1].

3. Ron's health problems developed during his 54 days of hospitalization following birth

Ron James Douglas was admitted to the neonatal intensive care unit at 1215 on 11/17/2006 and was discharged on 1/10/2007. He was treated for respiratory distress syndrome and chronic lung disease, apnea, bradycardia, sepsis, hyperbilirubinemia, and anemia. Ron also developed gastroesophageal reflux disease (GERD) and treated with Ranitidine.

Ron's cranial ultrasound exams performed on November 20th and December 18th were normal. Ron was given amino acids, NaCl, K acetate, K phosphate, calcium gluconate, magnesium, trace elements, and multivitamins IV during his hospitalization. He was discharged from the hospital on January 10, 2007.

Ron's weights at birth and at 54 days of age were 1287 and 2377 g, respectively. He gained 20.2 g/day. His length and head circumference (HC) at 54 days of age were 43 and 32 cm, respectively. His length and HC increased by 3.6 and 2.5 cm/month, respectively [1]. The clinical data collected during Ron's hospitalization are described in Section 3.1-11.

3.1 Respiratory distress syndrome, chronic lung disease, and apnea

Ron was diagnosed with respiratory distress syndrome (RDS) on November 17, 2006. His chest X-ray showed decreased aeration especially on the left lung. He was treated with Curosurf (surfactant). His chest X-ray taken on November 28th was bilaterally hazy. Ron was put on oxygen. He was given Synagis on December 12, 2006.

Ron developed apnea on 11/18/06 and treated with caffeine (4.0 mg/day). Blood analyses performed during Ron's 54 days hospitalizations showed that on many occasions, Ron's PCO₂ and bicarbonate levels were higher than the normal range and his PO₂ level was lower than the normal range (Table 1).

Table 1. Ron's blood gases measured during his first 52 days of life

Date	Time	PH	PCO ₂	PO ₂	O ₂ Satu%	HCO ₃ mMol/L	Be mMol/L
			mm Hg	mm Hg			
11/17/06	1242	7.38	39.7	39 L	72	23.3	-2
11/17/06	1616	7.40	37.1	49	84	22.8	-2
11/17/06	2115	7.35	39.4	54	86	21.5	-4
11/18/06	0358	7.33	38.3	45	78	20.3	-5
11/18/06	1003	7.31	39.6	50	82	19.7	-6
11/18/06	1612	7.34	37.1	53	86	20.2	-5
11/18/06	1724	7.39	31.3	52	87	19	-5
11/18/06	2012	7.37	34.9	40 L	74	20.3	-4
11/19/06	0808	7.35	37.6	26 L	46 L	20.8	-4
11/20/06	0411	7.31	43.8	33 L	57 L	21.9	-4
11/22/06	0942	7.41	27.8	43	80	17.5	-5
11/22/06	2215	7.32	45.3	41 L	72	23.4	-3
11/23/06	1030	7.35	41.2	44	77	22.8	-3
11/24/06	0417	7.35	46.0	42	74	25.4	-1
11/25/06	0411	7.35	55.1 H	29 L	51 L	30.1	3
11/26/06	---1	7.31	58.0 H	30 L	50 L	29.3	1
11/27/06	---	7.34	53.9 H	31 L	54 L	28.0	2
11/28/06	0424	7.33	56.7 H	29 L	49 L	29.6 H	2
11/28/06	1621	7.31	58.0 H	37 L	63 L	29.1 H	1
11/28/06	1920	7.34	55.2 H	30 L	53 L	29.7 H	2
11/29/06	---	7.38	47.6 H	29 L	53 L	28.1 H	2
12/01/06	---	7.35	44.5	31 L	55 L	24.6	-1
12/02/06	---	7.33	48.6	38 L	67 L	25.3	-1
12/06/06	2046	7.36	46.6	33 L	60 L	26.3 H	0
01/08/07	0406	7.43	36.8	37 L	73	24.2	0
Refer- ence Range		7.30 -	26-47 7.46	42- 58	71- 100	17-25	-3 to 4

¹ Time was not given; L: Lower than normal; H: Higher than normal.

3.2 Sepsis and treatment with antibiotics

Ron's mother tested positive for group B streptococcus. She had complications during labor that included chorioamnionitis and premature rupture of the membranes. The amniotic fluid was foul smelling. She was treated with ampicillin. Ron was treated with ampicillin and gentamicin per protocol for 8 days. His blood band neutrophil % was elevated on November 18, 2007 and it decreased following the treatment with antibiotics (Table 2).

Table 2. Ron's white blood cells

Date	Time	WBC x10 ³ /μL	NeutroPoly %	Neutro Band %	Lymphocyte %	Monocyte %	Esonophill %
11/17/06	1240	6.1	18	2	69	6	5
11/18/06	0355	5.9	58	12	22	7	1
11/19/06	0430	8.3	46	---	49	2	3
11/28/06	1915	11.8	53	5	34	5	3
12/01/06	0421	11.8	--- ¹	---	---	---	---
12/02/06	0445	7.1	32	8	56	3	1
Reference Range		7.4-14.6	14.7-35.3	0-10	41.3-65.4	7.1-13.7	0.0-6.4

¹ Not measured.

3.3 Development of anemia following birth

A blood analysis performed following birth on November 17, 2006 showed Ron had red blood cell (RBC) count, hematocrit (HCT) value, hemoglobin (HG) level, MCV, MCH, MCHC, and RDW % were higher than the normal range. However, Ron's RBC, HCT, and HG levels declined gradually and developed anemia (Table 3). His hematocrit value was 54.1% on November 18th and declined to 28.3% within 52 days.

A blood cell size morphology study indicates that Ron had microcytic anemia on December 2, 2006 (Table 4). Ron's reticulocyte count was 3.3% of the total red blood cell count on December 18, 2006. It increased to 4.8% on December 26th and 5.1% on January 8, 2007 (normal range 0.5-1.0%). He was treated with ferrous sulfate for 28 days and his treatment started on December 8, 2006.

Table 3. Ron's hematology values measured during his 52 days of hospitalization

Date	Time	RBC x 10 ⁶ /μL	HGB (g/dL)	HCT %	MCV (fL)	MCH (pg)	MCHC (g/dL)	RDW %	PLT x 10 ³ /μL
11/17/06	1240	4.71	18.9	54.1	115	40.2	35	15.9	-
11/18/06	0355	4.95	20.1	55.7	113	40.6	36.1	16.0	191
11/19/06	0430	4.99	19.1	56.0	112	38.2	34	16.1	296
11/24/06	0415	4.59	17.3	49.8	108	37.6	34.7	-	259
11/28/06	1915	4.52	15.9	47	105	35.2	33.5	17.5	291
11/29/06	0438	--- ¹	16.0	47	---	---	---	---	---
11/30/06	0544	---	14.3	42	---	---	---	---	---
12/01/06	0421	---	14.3	42	105	35.2	33.5	---	---
12/02/06	0445	3.85	13.2	39.9	104	34.4	32.2	17.8	313
12/05/06	0440	---	13.6	40	---	---	---	---	---
12/12/06	0430	---	---	34.3	---	---	---	---	---
12/18/06	0405	---	---	35.4	---	---	---	---	---
12/21/06	1320	3.27	---	-	---	---	---	---	---
12/26/06	0415	---	---	31.7	---	---	---	---	---
01/08/07	0426	---	---	28.3	---	---	---	---	---
Reference Range		3.1-4.5	9.5-13.5	29.0-41.0	89-101	30.1-33.8	32-35	15.2-17.4	150-500

¹ Not measured

Table 4. Ron's Red blood cell morphology

Date	Micro-cytic	Macro-cytic	Hypo-chromia	Poly-chromia	Aniso-cytosis
11/17/06	--- ¹	+3	---	+1	+1
11/18/06	---	+3	---	+1	+1
11/19/06	---	+3	---	+2	+1
11/28/06	---	+2	---	+1	+1
12/02/06	+2	+1	+1	+1	+1

¹ Not measured

3.4 Hyperbilirubinemia

Ron developed hyperbilirubinemia on November 18, 2006 and was treated with phototherapy for 13 days. His serum bilirubin level reached a peak level of 9.9 mg/dL on December 18, 2006 and it reduced to 2.4 mg/dL on January 6, 2007 (Table 5). Ron's jaundice caused by the rapid destruction of his red blood cells and the inability of his liver to conjugate all bilirubin produced.

Ron and his mother have type O positive blood and Ron was Coombs negative. The activity of glucose-6-phosphate dehydrogenase (G6pd) in Ron's RBC on December 21, 2006 was 486 units/L (normal range: 146-376). These data indicate that Ron's hemolytic anemia was not caused by immune problem or by the lack of G6pd.

Table 5. Ron's serum bilirubin levels

Date	Total Bilirubin (mg/dL)	Direct Bilirubin (mg/dL)	Indirect Bilirubin (mg/dL)
11/18/06	6.2	0.4	5.8
11/19/06	7.5	0.3	7.2
11/20/06	7.0	0.2	6.8
11/21/06	6.8	0.3	6.5
11/27/06	5.5	0.4	5.1
12/12/06	7.2	--- ¹	---
12/13/06	6.6	0.5	6.1
12/18/06	9.9	0.5	9.4
12/20/06	9.0	---	---
12/21/06	8.9	---	---
12/23/06	8.5	---	---
12/26/06	7.8	0.4	7.4
12/29/06	7.5	0.6	6.9
01/04/07	4.4	0.3	4.1
01/06/07	2.4	---	---
Reference Range	0.1-0.8	0.1-0.5	0.0-1.0

¹ Not measured

3.5 Hyperphosphatemia

A blood analysis performed at one day following birth showed that Ron's phosphate level was slightly elevated above the normal range. However, blood analyses performed at 39 and 46 days following birth revealed that Ron was suffering from hyperphosphatemia. His serum phosphate level reached a peak of 8.4 mg/dL (Table 6).

Ron serum total calcium level was slightly below the normal range on November 18th and was treated with calcium gluconate (IV). His serum calcium level stayed within the normal range between November 20th and December 26th. Ron's serum levels of the ionized calcium and magnesium were also within the normal range ((Table 6).

Table 6. Ron's serum phosphate, calcium, and magnesium levels measured during 39 days following birth

Date	Phos. (mg/dL)	Calc. (mg/dL)	Calc. Ionized (mmol/L)	Magnes. (mg/dL)
11/18/06	6.9	8.3	1.17	1.5
11/19/06	6.9	8.8	---	2.4
11/20/06	5.8	9.5	---	2.4
11/21/06	6.0	10.3	---	2.8
11/22/06	6.1	10	---	---
11/23/06	6.1	10.3	---	---
11/24/06	5.9	9.5	---	---
11/25/06	--- ¹	10.4	---	---
11/27/06	---	10.4	---	2.3
11/28/06	---	---	1.43	---
11/29/06	---	---	1.34	---
11/30/06	---	---	1.39	---
12/01/06	---	---	1.31	---
12/02/06	---	---	1.46	---
12/05/06	---	---	1.33	---
12/18/06	8.4 H	10.5	---	2.6
12/26/06	8.2 H	10.3	---	2.7
Ref. Range	3.5-6.5	9.1-10.5	1.10-1.40	1.5-2.5

¹ Not measured

3.6 Hyponatremia and hyperkalemia

Ron had low serum sodium level at one day following birth and was treated with sodium chloride. His serum potassium level was within the normal range following birth. However, he developed hyperkalemia on December 21, 2006 due to acidosis. His serum chloride level was within the normal range (Table 7).

Table 7. Ron's serum sodium, chloride, and potassium levels measured during the 39 days following birth

Date	Sodium (mMol/L)	Chloride (mMol/L)	Potass. (mMol/L)
11/18/06	128	98	4.3
11/19/06	146	111	3.1
11/20/06	143	110	3.5
11/21/06	144	109	3.8
11/22/06	140	107	4.3
11/23/06	134	99	3.9
11/24/06	133	100	3.5
11/25/06	136	99	4.7
11/27/06	140	103	5.1
11/28/06	136	107	5.0
11/29/06	138	112	6.2
11/30/06	138	108	4.4
12/01/06	133	109	6.0
12/02/06	135	103	4.6
12/05/06	134	106	4.7
12/18/06	133	100	5.6
12/26/06	138	104	5.4
Reference Range	135-145	96-112	3.6-5.5

3.7 Hypoproteinemia

Ron's serum albumin and total protein levels were below the normal range on November 18, 2006. His serum albumin increased on December 18th and 26th but stayed below the normal range. His total protein level became within the normal range on December 18th (Table 8).

Table 8. Ron's serum protein levels

Date	Albumin (g/dL)	Globulin (g/dL)	T. Protein (g/dL)
11/18/06	2.4	1.9	4.3
11/19/06	2.0	1.4	4.7
11/20/06	1.9	1.6	4.9
11/21/06	2.3	1.3	5.2
11/27/06	2.7	--- ¹	4.7
12/18/06	3.3	2.4	5.7
12/26/06	3.0	1.9	4.9
Reference Range	3.4-4.8	1.6-2.7	5.0-7.5

¹ Not measured

3.8 Hypercreatininemia and elevated serum BUN level

A blood analysis revealed that Ron's serum creatinine level was higher than normal at birth and it reached a peak of 1.2 mg/dL at 12 days following birth. However, it decreased gradually and reached a normal level on December 26th (Table 9).

Ron's blood BUN level was within the normal range following birth. However, it increased gradually and reached a peak level of 31 mg/dL on November 29th. His BUN level decreased gradually after November 29th and it reached a normal level on December 5th (Table 9).

Ron's serum levels of liver enzymes were within the normal range (Table 10). The increased creatinine and BUN levels in

Ron's blood indicate that his kidney was unable to eliminate these metabolic products.

Table 9. Ron's serum creatinine, BUN, and glucose levels

Date	Creatin. (mg/dL)	BUN (mg/dL)	Glucose (mg/dL)
11/18/06	1.1	18	77
11/19/06	0.9	24	78
11/20/06	1.1	24	90
11/21/06	1.0	22	105
11/27/06	0.8	16	76
11/28/06	0.9	20	71
11/29/06	1.2	31	101
11/30/06	0.9	31	--- ¹
12/01/06	0.8	25	82
12/02/06	0.8	24	78
12/05/06	0.7	15	---
12/18/06	0.4	8	104
12/26/06	0.4	<5	68
Reference Range	0.3-0.6	5-17	60-100

¹ Not measured

Table 10. Ron's serum levels of enzymes

Date	Alk phospho (IU/L)	ALT (IU/L)	AST (IU/L)
11/19/06	103	10	37
11/20/06	94	8	24
11/21/06	96	7	23
11/27/06	172	5	30
12/18/06	233	17	35
12/26/06	246	29	19
Reference Range	170-390	5-50	22-60

3.9 Low blood thyroid hormone level at birth

A thyroid screening test performed on November 23, 2006 revealed that Ron's thyroxine (T4) level in the blood was in the lower three percentiles of the population. His T4 and the thyroid stimulating hormone (TSH) levels in the blood increased significantly on December 8th (Table 11).

Table 11. Ron's Newborn Screening Test Results

Test	11/23/2006	12/08/2006	Reference
Thyroxine (T4)	3.31 µg/dL	8.72 µg/dL	Age adjusted
TSH	< 2 µIU/mL*	6.20 µIU/mL	Age adjusted
Phenylalanine	<200 µM	<200 µM	<200 µM
Biotinidase	Has color	Has color	Has color
CAH (17-OHP)	70.34 ng/mL	18.54 ng/mL	Age adjusted
GALT	Fluorescence	Fluorescence	Fluorescence
Amino Acids	Normal	Normal	Normal
Acylcarnities	Normal	Normal	Normal

3.10 Blood clot in aorta

Ron's Echo test performed on November 27th showed possible small abdominal aortic clot without obstruction to blood flow.

3.11 Retinopathy of prematurity

Ron's first retinal exam performed on December 12, 2006 revealed stage 0 retinopathy of prematurity (ROP) involving the anterior zone 3 bilaterally. His retinal exam on December 26, 2006 showed regression of the previously noted stage 0 ROP in both eyes.

4. Ron's health condition following his discharge from the hospital on January 10, 2007

Ron James Douglas was discharged from the hospital on January 10, 2007. He was put on oxygen breathing until February 2007 and remained on the apnea monitor. He was breastfed and had a history of vomiting episodes. He was diagnosed with gastroesophageal reflux disease (GERD) and treated with Reglan and Zantac.

Ron was given multivitamins and iron as treatment for his anemia. He was vaccinated with pneumococcal conjugate vaccine (PCV) and Pediarix on January 17, 2007. Pediarix consists of five vaccines that include Diphtheria, Tetanus Toxoids, and Acellular Pertussis Adsorbed; Hepatitis B (Recombinant); and Inactivated Poliovirus Vaccine Combined [2].

Ron suffered from cardiopulmonary arrest on March 10, 2007 and was taken to Renown Regional Medical Center. He was pronounced dead on March 11th [3, 4]. His weight gain rate between January 10th and March 6th was 30.6 g/day. However, his weight gain rate between March 6th and 10th was 69 g/day. In addition, his weight was increased by 213 g between March 10th and 11th (Tables 12, 13). These data indicate that Ron's was not eliminating water at a normal rate and had kidney problems.

4.1 Ron's weight gain and growth rates between January 10th and March 11th

Ron's exam on January 10, 2007 revealed that his weight was 2.370 kg. He gained 1.083 kg in 54 days (21.2 g/day). His length and head circumference (HC) were 43.0 cm and 32 cm, respectively. His length and HC increased at the rate of 3.61 cm/month and 2.5 cm/month, respectively.

Ron was also examined on February 6th and 20th and March 6th. His weight, length and HC measurements are presented in Table 12. His weight gain rate between January 10th and March 6th was 30.6 g/day, which is 151% of his weight gain rate during the period of November 17, 2006 and January 10, 2007. Ron's weight gain rate was 69 g/day during the period of March 6th and March 10th (Table 13).

Table 12. Ron's weight and body measurement

Date	Age (days)	Weight (g)	Length (cm)	HC (cm)
11/17/06	Birth	1287	36.5	27.5
01/10/07	54	2377	43	32.0
02/06/07	81	3210	---	--- ¹
02/20/07	95	3700	49.3	---
03/06/07	109	4060	---	---
03/10/07	113	4337	52.1	---
03/11/06	114	4550	51.5	38.5

¹ Not measured

Table 13. Ron's weight gain rate at different intervals of his life

Period	Duration (days)	Weight gained (g)	Weight gain rate (g/day)
11/17/06-01/10/07	54	1090	20.2
01/11/06-2/06/07	27	833	30.9
02/07/07-2/20/07	14	490	35
02/21/07-03/06/07	14	360	25.7
03/07/07-03/10/07	4	277	69
03/10/07-03/11/07	1	213	213
03/07/07-03/11/07	5	490	98

4.2 Ron's cardiopulmonary arrest and treatment given by the paramedics

Ron's mother left to work at about 0600 on March 10th. In the morning of March 10th, the father fed Ron about 2 ounce of milk. Ron relaxed and burped once then cried, choked, and vomited.

The father immediately performed back blows and suction to get out as much as of the emesis as possible. He used a bulb syringe to collect fluids from Ron's mouth. He saw blood came out from Ron's mouth and nose. He attempted to clear Ron's airway with his finger.

Ron's father called Ron's grandmother when the baby became unresponsive and she told him to call 911. He called 911 at 0726 hours. The grandmother arrived at the residence and began chest compressions on Ron prior to the arrival of the paramedics.

Careflight arrived on the scene at 0739 and the paramedics assumed the baby's care. Ron was flaccid, cyanotic, and had cardiac arrest. They observed blood tinged mucus draining out of Ron's nostrils and a significant amount of blood tinged mucus present in Ron's upper airway.

The paramedics performed CPR and intubated Ron. They also placed intraosseous line and gave Ron epinephrine (0.3 mL) and fluids. Ron was transferred to Renown Regional Medical Center (RRMC). The paramedic left the scene at 0801 and arrived at RRMC at 0806 [3, 4].

5. Ron's hospitalization on March 10, 2007, clinical test, diagnoses, and treatment given

The paramedics brought Ron James Douglas to Renown Regional Medical Center at 0806 on March 10th. Ron was transferred to the Pediatric Intensive Care Unit (PICU). Ron was unresponsive and making some agonal respirations. He was intubated. Examination revealed that Ron's left pupil was approximately 3 mm and his right pupil was about 1 mm.

Ron's ears were clear bilaterally and his oral pharynx was pink, and moist. No erythema or exudates was noted. Ron's lungs were clear to auscultation. He experienced episode of cardiac instability. His abdomen was slightly distended and no hepatosplenomegaly was noted.

Ron's skin had no rash, bleeding, or injury and his extremities were slightly cold. He had a temperature of 36.1°C, a pulse of 180/min., a respiratory rate of 25/min., and a blood pressure of 45/58 mm Hg. Ron's weight and height on March 10th were 4337 g and 52.07 cm, respectively.

A CT scan performed at 1 hour following Ron's admission to the hospital (FAH) showed Ron had a severe anoxic brain injury. A blood analyses performed at 1-3 hours FAH revealed that Ron had the following abnormal conditions:

- 1) Severe hypocalcemia. Ron's total serum calcium level was 6.2 mg/dL. He also suffered from hypokalemia and hyperchloremia (Table 14). His serum phosphate level was not measured.
- 2) Metabolic and respiratory acidosis. Ron had a blood pH of 7.13, PCO₂ of 58.8 mm Hg, and bicarbonate level of 19.0 mmol/L. He was treated with sodium bicarbonate IV that raised his blood pH to 7.5 (Table 15).
- 3) Elevated serum levels of alkaline phosphatase, SGOT, and SGPT enzymes and low blood urea nitrogen (BUN) level (Table 16).
- 4) Elevated levels of prothrombin time (PT), Partial Prothrombin Time (PPT), and International normalized ratio (Table 17).
- 5) Hypoproteinemia, hyperglycemia, and anemia (Tables 18, 20, 21).

Furthermore, a urine analysis performed at 2 hours FAH showed a significant amount of protein, blood, red blood cell, white blood cells, and bacteria in Ron's urine (Table 19).

Ron's eyes were examined at 1245 on March 10th and revealed severe retinal hemorrhages in both eyes. There was no evidence of infection or trauma. A second CT scan was performed at 0855 on March 11th revealed Ron's brain edema became more severe. He also had a small amount of left parenchymal hemorrhage and an apparent subarachnoid hemorrhage (Table 23).

Ron was given blood transfusions and treated with epinephrine, zantac, multivitamins, insulin and fentanyl, IV fluids, dopamine, Rocephin, Clindamycin but he did not show improvement. His blood pressure decreased to 40/20 at 1030 on March 11th and was pronounced dead at 1042. Resuscitation was not attempted. The clinical data collected in the hospital are described in Section 5.1-10.

5.1 Hypocalcemia, hypokalemia, hyperglycemia

A blood analysis performed at 40 minutes following Ron's admission to the hospital (FAH) revealed that he was suffering from a severe hypocalcemia. He was treated with calcium. However, his serum calcium level stayed below normal (Table 14).

The likely causes of Ron's hypocalcaemia were hyperphosphatemia and hypoparathyroidism. Ron's phosphate level in the blood was not measured on March 10th. However, his phosphate level in the blood was elevated on December 18 and 26, 2006 (Table 6). Furthermore, Ron suffered from hypokalemia, and hyperchloremia. The likely cause of Ron's hypokalemia and hyperchloremia was kidney problems.

Table 14. Ron's serum electrolytes levels on March 10, 2007

Time	Calcium (mg/dL)	Na ⁺ (mMol/L)	K ⁺ (mMol/L)	CL ⁻ (mMol/L)
0846	6.2 ¹	139	2.80	119
1100	8.1	137	5.3	110
1615	7.3	140	5.3	114
2200	7.4	146	3.80	120
Reference Range	9.1-10.5	135-145	3.6-5.5	96-112

¹Critically low.

5.2 Acidosis

A blood analysis performed at 3 hours FHA showed that Ron was suffering from metabolic and respiratory acidosis. He was treated with sodium bicarbonate IV that raised his blood pH from 7.13 to 7.50. His PO₂ and O₂ blood saturation were also very low (Table 15).

Table 15. Ron's blood gases measured following his hospitalization on March 10th

Date	Time	pH	PO ₂	O ₂	PCO ₂	HCO ₃ ⁻ mmol/L	BE mmol/L
			mm Hg	Sat %	mm Hg		
3/10/07	1100	7.13	33.8	47	58.8	19	-11
3/10/07	1615	7.26	41.2	69.2	38.9	17	-10
3/10/07	2200	7.50	42.5	89.2	21	16	-5
3/11/07	0530	7.29	32.1	54.7	41.3	19	-7
Reference Range		7.35-7.45	83-108	95-100	32-45	20-24	-3.3-1.2

5.3 Liver damage and blood clotting problems

A blood analysis performed at about 3 hours FAH revealed that Ron had elevated levels of alkaline phosphatase, SGOT, and SGPT enzymes in serum. His blood urea nitrogen (BUN) in serum was very low (Table 16). These data indicate that Ron was suffering from liver injury that reduced its ability to convert ammonia to BUN.

Ron's prothrombin time (PT), partial thromboplastin time (PTT), and International Normalized Ratio (INR) were elevated at 3 hour FAH (Table 17). Most of the blood clotting factors is synthesized in the liver and a significant liver injury usually lead to blood clotting problems.

Table 16. Ron's serum enzymes, bilirubin, and BUN levels on March 10th

Time	Alk.Phosphotase (IU/L)	AST/SGOT (IU/L)	ALT/SGPT (IU/L)	T. Bilirub. (mg/dL)	BUN (mg/dL)
0846	--- ¹	-	-	0.7	<5.0
1100	430	187	40	1.5	<5.0
1615	348	151	42	1.9	<5.0
2200	243	123	44	2.8	<5.0
Reference Range:	60-321	18-53	10-32	<2.0	5-27

¹ Not measured.**Table 17. Ron's blood clotting indicators measured on March 10th**

Measurements	1100	Reference Range
PT (seconds)	23.8	11.9-14.8
APTT (seconds)	40.5	26-37
INR	1.92	0.8-1.2

5.4 Hypoproteinemia, proteinuria, and hematuria

A blood analysis performed at 40 minutes FAH showed that Ron suffered from hypoproteinemia (Table 18). A urine analysis performed at 2 hours FAH revealed significant amount of protein, blood, red blood cell, white blood cells, and bacteria in Ron's urine (Table 19). These data indicate that Ron was suffering from kidney damage.

Table 18. Ron's serum creatinine, protein, and BUN levels on March 10th

Measurements	0846	1100	1615	2200	Reference Range
Creatinine (mg/dL)	0.3	0.4	0.3	0.3	0.3-0.6
T. Protein (g/dL)	2.40	3.90	4.40	4.0	4.3-6.9
Albumin (g/dL)	1.7	2.8	3.0	3.2	2.7-4.8
Globulin (g/dL)	0.7	1.1	--- ¹	---	1.6-2.7

¹ Not measured.

5.5 Hyperglycemia

A blood analysis performed at 40 minutes FAH showed that Ron had elevated blood glucose level of 250 mg/dL. His glucose level increased significantly at 8 hours FAH (Table 20). He was treated with insulin. His urine was negative for glucose and ketone bodies.

The likely cause of Ron's hyperglycemia was the inability of tissues to use glucose due to the high level of ammonia in the blood. His blood ammonia level was not measured. However, Ron's low level of BUN in blood indicates that his liver was not converting ammonia to urea.

Table 19. Ron's urine analysis at 1034 on March 10th

Measurements	Values	Reference Range
Color	Yellow	Yellow
Clarity	Cloudy	Clear
Specific gravity	1.016	1.005-1.030
PH urine	5.5	5.0-8.0
Glucose (mg/dL)	Negative	Negative
Ketones (mg/dL)	Negative	Negative
Protein (mg/dL)	30	Negative
Bilirubin-Ur	Negative	Negative
Nitrite	Negative	Negative
Leuk esterase	Negative	Negative
Occult blood	Large	Negative
WBC/HPF	5-10	0-4
Red blood cell/HPF	10-20	0-4
Epithelia cell	Moderate	Negative
Bacteria	Moderate	Negative
Reducing sugar	2	Negative

Table 20. Ron's blood glucose levels on March 10th

Time	Blood Glucose (mg/dL)
0846	250
1100	341
1200	358
1403	323
1615	216
1825	189
2035	199
2204	182
2346	192
Reference Range	60-100

5.6 Ron's anemia observed on March 10th

A blood analysis performed at 40 minutes FAH showed that Ron was suffering from a severe anemia. His red blood cell count, hematocrit value and hemoglobin level were about 50% of normal (Table 20). Red blood cell morphology study revealed a polychromacia of +2, anisocytosis of +1, and microcytosis of +1. He was given blood transfusion at 1100 and 1359 on March 10th.

Ron's platelet count at 40 minutes FAH was $220 \times 10^3/\mu\text{L}$ and increased by 156% as a result of the blood transfusions received. However, his platelet count reduced by 52% within 11 hours (Table 21). These data indicate that Ron was suffering

from disseminated intravascular coagulation (DIC) due to coagulation problems.

Table 21. Ron’s hematology values measured March 10th

Measurements	0846	1100	1615	2200	Ref. Range
Red blood cell	2.37	3.07	5.09	4.87	3.8-5.40
Hematocrit%	19.4	23.9	40.9	37.5	32-42
Hemoglobin(g/dL)	6.2	8.0	14.4	13.4	32-42
MCV fL	82.1	77.8	80.3	76.8	72-88
MCH pg	26.0	26.1	28.3	27.5	24-30
MCHC (g/dL)	31.7	33.5	35.2	35.8	32-36
RDW %	16.9	17.2	22.0	16.2	11-15
Platelet x10 ³ /μL	220	344	220	165	140-340

5.7 Evidence of bacterial infection

Ron’s white blood cell and differential cells counts were within the normal range at 40 minutes FAH. However, at 10 hours FAH, Ron’s neutrophil band count was significantly increased. He was treated with antibiotics (clindamycin and ceftriaxone) and his neutrophil band count reduced to a normal level (Table 22).

Table 22. Ron’s white blood cell and differential counts on March 10th

Measurements	0846	1100	1615	2200	Ref. range
WBC x 10 ³ /μL	7.7	10.5	11.0	9.9	5.0-13.0
Neutrophil %	23.0	56.6	61.0	63.0	30-40
Band %	2	-	17	5	0-8
Lymphocyte %	72	36.6	17.0	23.0	45-60
Monocytes %	1.0	5.1	4	9	1-5
Eosinophil %	2	1.6	1	0	1-5

5.8 Retinal hemorrhage

Ron’s eyes were examined at 1245 on March 10th and his exam revealed severe retinal hemorrhages in both eyes. No evidence of infection or trauma was observed in his eyes.

5.9 Development of intracranial bleeding following hospitalization

A CT scan exam performed at 1 hour FAH showed that Ron’s brain had anoxic changes and mild edema. His CT head exam taken at 25 FAH showed an increase in the brain edema. It also revealed the presence of subarachnoid and parenchymal hemorrhage, which was not observed at 1 hour FAH (Table 23).

Table 23. Ron’s CT head exams performed at 1 and 25 hours following admission

Date & Time	Findings
3/10/07 0902	<ul style="list-style-type: none"> Diffuse anoxic brain lesion involving the supratentorial brain parenchyma. Loss of the gray/white matter differentiation. Somewhat heterogenous hyperdense appearance of the falx and tentorium. No evidence of calvarial fracture.
3/11/07 0855	<ul style="list-style-type: none"> Increased brain swelling and edema compared to the prior CT. The basilar cisterns were not well visualized and ventricles appear smaller than on the prior CT. Subarachnoid hemorrhage appears to be present in the basilar cistern and in several of the sulci. A small amount of parenchymal hemorrhage appears to be present in the left periventricular white matter.

5.10 Drug test

Ron’s blood sample collected on March 10, 2007 tested negative for the following drugs, medications, and alcohol: Acetaminophen, amphetamine/methamphetamine, benzodiazepines, cocaine/cocaine metabolite, ethanol, opiates, salicylate, THC-metabolites.

6. Autopsy findings, the medical examiner’s opinion, and the likely causes of Ron’s cardiopulmonary arrest, bleeding, and rib fracture

Ron James Douglas was admitted to the hospital at 0806 on March 10, 2007 and was pronounced dead at 1042 on March 11th. Dr. Katherine P. Raven performed the autopsy on Ron’s body on March 12th. She found subdural, subarachnoid, and retinal hemorrhages and acute rib fracture of the left anterolateral 6th rib.

Raven alleged that Ron’s death was caused by blunt trauma to the head and trunk [5, 6]. The examination performed by the paramedics and the treating physician did not reveal the presence of injury caused by trauma on Ron’s body. In addition, the head CT scans performed on March 10th and 11th did not show skull fracture. My review of the clinical data and the pertinent medical studies to Ron’s case reveals the following:

1) Ron was suffering from a severe hypocalcemia on March 10th that caused laryngeal spasm and cardiopulmonary arrest. Ron’s serum calcium level at 40 minutes following his admission to the hospital (FAH) was 6.2 mg/dL. Hypocalcemia is defined as the total blood calcium level below 9.0 mg/dL. The likely causes of Ron’s hypocalcemia were hypoparathyroidism and hyperphosphatemia (Section 7).

2) The increased level of phosphate in the blood led to the binding of phosphate with calcium and the deposition of calcium phosphate in liver and kidney, causing injuries to these organs. A blood analysis performed at about 3 hours FAH revealed that Ron had elevated levels of alkaline phosphatase, SGOT, and SGPT enzymes in serum. A urine analysis performed at 2 hours FAH revealed that Ron’s urine contained significant amount of protein, blood, red blood cell, and white blood cells (Section 7).

3) A blood analysis performed on March 10th showed that Ron was suffering from a severe anemia. Ron's red blood cell count, hematocrit value and hemoglobin level were about 50% of normal at 40 minutes FAH. Clinical data and biomarkers indicate that Ron was suffering from hemolytic anemia and his problem developed following birth. However, he was not monitored following his release from the hospital on January 10, 2007 to detect the problem (Section 8).

4) Ron's thymus was involuted and replaced by fat. Ron had several risk factors that are known to cause reduction in thymus size and involution. These include premature birth, chorioamnionitis, infections, and the treatment with corticosteroid. Ron was born premature at 28 weeks and 5 days gestation and his weight was 1.287 kg. His mother was treated with corticosteroid prior to labor (Section 9).

5) Ron's bleeding developed following his admission to the hospital on March 10th was not limited to the head region. He also had pulmonary bleeding and subdural and epidural bleeding over the cauda equina of the spinal cord. The bleeding in Ron's lungs was not reported by the medical examiner (Section 10).

6) The likely causes of Ron's bleeding were acute liver injury, treatment with high dose of epinephrine, and disseminated intravascular coagulation (DIC). In addition, Ron was suffering from a severe anemia and retinal bleeding has been reported in individuals suffering from severe anemia.

7) The likely causes of Ron's brain edema were anoxia, acidosis, treatment with high doses of sodium bicarbonate, and irritation from bleeding. Most of Ron's brain edema developed after his admission to the hospital on March 10th. The ischemic changes and necrosis observed in Ron's brain were caused by anoxia, ischemia, treatment with high doses of sodium bicarbonate, and increased intracranial pressure (Section 11).

8) The likely cause of Ron acute fracture of the left anterolateral 6th rib was cardiopulmonary resuscitation (CPR) performed on March 10th. Ron received chest compressions prior to the arrival of the paramedics and then the paramedics performed CPR. Single and multiple rib fractures have been observed in infants who received CPR following cardiac arrest (Section 12).

7. The likely causes of Ron's severe hypocalcemia, symptoms, and lesions observed in organs

A blood analysis performed at 40 minutes following Ron's admission to the hospital (FAH) revealed that Ron was suffering from a severe hypocalcemia. His serum calcium level was 6.2 mg/dL (Table 14). Hypocalcemia is defined as the total blood calcium level blood less than 9.0 mg/dL.

Ron had a normal serum calcium of 10.3 mg/dL on December 26, 2006 (Table 6). His serum calcium level was reduced by 40%. The likely causes of Ron's hypocalcemia were hypoparathyroidism and hyperphosphatemia.

Ron's serum phosphate level was not measured on March 10th. However, he had elevated serum phosphate levels of 8.4 mg/dL and 8.2 mg/dL on December 18th and 26th, 2006, respectively (Table 6). He was suffering from hyperphosphatemia due

to parathyroid problem. However, the functions of the parathyroid glands were not monitored at any time during Ron's life. The parathyroid gland's functions are usually assessed by measuring the levels of serum Parathyroid hormone (PTH) and Calcitonin (CT) [7].

Individuals suffer from hypocalcemia usually develop laryngeal spasm, convulsion, seizure, and/or cardiac arrest. Mallet stated that the clinical manifestations of hypocalcaemia in children are neurological disorders such as seizures, respiratory disorders with possible laryngospasm, and/or severe cardiac disorders that may result in sudden death [8].

De Holanda and De Melo evaluated 89 neonates developed neonatal seizures and 19 (21.3%) of them had hypocalcemia [9]. In addition, Rowińska *et al.* reported two cases of girls developed epileptiform convulsive seizures and consciousness disturbances due hypocalcaemia secondary to hypoparathyroidism [10].

Furthermore, Tseng *et al.* reported four cases of full-term infants developed hypocalcemia and hyperphosphatemia due to transient hypoparathyroidism. They became symptomatic at the age of 6 to 17 days old. Seizure was the major symptom in three infants and one infant had a high pitch crying, irritability, and opisthotonus.

Laboratory data revealed that these infants had serum calcium levels of 4.7 to 6.3 mg/dL, phosphorus levels of 6.8 to 9.2 mg/dL, and magnesium levels of 1.2 to 2.8 mg/dL. The parathyroid hormone levels were abnormally low in two cases (<13 pg/ml and 5.7 pg/ml) and subnormal in the other two (25.2 pg/ml and 22.2 pg/ml) [11].

Furthermore, Halterman and Smith evaluated a case of a breast-fed infant who presented to the pediatric emergency department with profound stridor because of hypocalcemia. Stridor resulted from laryngospasm due to hypocalcemia. The infant responded to intravenous calcium chloride with rapid resolution of symptoms [12].

Cardiac problems are well documented in individuals suffering from hypocalcemia. For example, Hurley and Baggs reported a case of a 73-year-old man with hypocalcemia-induced heart failure due to hypoparathyroidism and hypocalcemia. His serum total calcium at the time of presentation was 5.36 mg/dL. Ventricular function, as documented by echocardiogram, showed improvement with correction of serum calcium levels [13].

In addition, Lehmann *et al.* evaluated a case of a 25-year-old woman presented to the hospital with chest pain, ECG changes, and laboratory findings suggestive of myocardial infarction. Cardiac catheterization showed impaired left ventricular performance but otherwise normal coronary arteries. Laboratory analyses revealed primary hypoparathyroidism. She was treated with calcium and vitamin D(3) and improvement in laboratory findings as well as echocardiographically determined left ventricular performance were observed [14].

Hypocalcemia was the likely cause of Ron's choking and cardiopulmonary arrest occurred on March 10th. In addition, the increased level of phosphate in the blood had led to the binding of phosphate with calcium and the deposition of calcium phosphate in liver and kidney causing injuries to these organs.

A blood analysis performed at about 3 hours FAH revealed that Ron had elevated levels of alkaline phosphatase, SGOT,

and SGPT enzymes in serum. His blood urea nitrogen (BUN) in serum was very low (Table 16). These data indicate that Ron was suffering from liver injury that reduced its ability to convert ammonia to BUN.

A urine analysis performed at 2 hours FAH revealed that Ron's urine contained significant amount of protein, blood, red blood cell, and white blood cells (Table 19).

In addition, Ron's weight measured on March 11th indicates that he gained a significant amount of weight prior to his cardiopulmonary arrest due to fluid retention. Ron's weight gain rate between March 6th and March 11th was 98 g/day, which is 381% of his weight gain rate during the period of February 20th and March 6th (Table 13).

8. Progress of Ron's hemolytic anemia and biomarkers

A blood analysis performed on March 10, 2007 showed that Ron was suffering from a severe anemia. Ron's red blood cell count, hematocrit value and hemoglobin level were about 50% of normal at 40 minutes following his admission to the hospital (Tables 21, 24). Red blood cell morphology study revealed a polychromasia of +2, anisocytosis of +1, and microcytosis of +1.

The following clinical data and biomarkers indicate that Ron was suffering from hemolytic anemia and his problem developed following birth. However, he was not monitored following his release from the hospital on January 10, 2007 to detect the problem (Table 24).

1) A blood analysis performed on November 18, 2006 showed that Ron had red blood cell (RBC) count, hematocrit (HCT) value, hemoglobin (HG) level higher than the normal range. However, his RBC, HCT, and HG levels declined gradually. His hematocrit value reduced from 54.1% to 28.3% within 52 days (Tables 3, 24). A blood cell size morphology study indicates that Ron had microcytic anemia on December 2, 2006 (Table 4) and was treated with ferrous sulfate.

2) Ron's reticulocyte count was 3.3% of the total red blood cell count on December 18, 2006. It increased to 4.8% on December 26th and 5.1% on January 8, 2007 (normal range 0.5-1.0%). These data indicate that he was losing RBC rapidly and immature RBC released from bone marrow to the blood to compensate for the lost RBC.

3) Ron developed hyperbilirubinemia on November 18, 2006 and his serum total bilirubin level reached a peak of 9.9 mg/dL (95% unconjugated bilirubin) on December 18, 2006 (Table 5). He was treated with phototherapy. However, his serum unconjugated bilirubin level remained elevated (4.1 mg/dL) on January 2, 2007. Ron's jaundice caused by the rapid destruction of his red blood cells and the inability of his liver to conjugate all bilirubin produced.

4) The decline of Ron's RBC numbers and hemoglobin concentration in the blood continued at a significant rate following his release from the hospital on January 10, 2007 (Table 24). Ron's RBC numbers and HCT value decreased by 52% and 65%, respectively, during the period from November 18, 2006

and March 10, 2007. His HG level reduced by 69% during the same period (Table 24).

Table 24. Progress reduction of red blood cell number and hemoglobin concentration in Ron's blood

Measurements	11/18/06*	12/02/06	01/08/07	03/10/07
RBC x 10 ⁶ /μL	4.95	3.85	---2	2.37
RBC % of initial ¹	100	77.8	---	47.9
HGB (g/dL)	20.1	13.2	---	6.2
HGB % of initial ¹	100	65.7	---	30.8
HCT%	55.7	39.9	28.3	19.4
HCT% of initial ¹	100	71.6	50.8	34.8

¹ Initial value on 11/18/06;

² Not measured

9. The likely causes of Ron's thymic atrophy

At autopsy on March 12, 2007, Dr. Katherine P. Raven reported that Ron's thymus was involuted and replaced by fat [5]. However, in her court testimony on January 22, 2008, she stated that Ron's thymus was not replaced by fat but he had involuted thymus because he was stressed prior to death [6]. Raven did not weigh Ron's thymus or provide microscopic description of the thymus.

Ron admitted to the hospital at 0806 on March 10th and was pronounced dead at 1042 on March 11th. He was hospitalized for 26 hours. There is no single medical study to support Raven's opinion that one-day hospitalization caused involution of the thymus in a 16 week-old healthy infant. Raven alleged that Ron was healthy prior to his cardiopulmonary arrest on March 10th. The average thymus weight in a 16 week-old infant is about 25 g.

In addition, Ron's spleen and lymph nodes were grossly and microscopically appeared normal and these organs usually affected by stress. Raven stated that Ron's spleen had a smooth and glistening capsule and an unremarkable parenchyma with usual anatomical features. His spleen weight was 20 g. Ron's lymph nodes showed no pathologic change.

Ron had several risk factors that are known to cause reduction in thymus size and involution. These include premature birth, chorioamnionitis, infections, and the treatment with corticosteroid. Ron was born premature at 28 weeks and 5 days gestation and his weight was 1.287 kg. His mother was treated with corticosteroid prior to labor.

The complications during labor were chorioamnionitis and premature rupture of the membranes. The amniotic fluid was foul smelling. Ron's mother tested positive for Group B Streptococcus and was treated with ampicillin.

Toti *et al.* evaluated the morphologic modifications in the thymus of fetuses with histologically proven chorioamnionitis and newborn infants with chorioamnionitis and proven sepsis. Their main findings included (1) decreased organ volume (ANOVA, $P < 0.0024$); (2) reduced corticomedullary ratio ($P < 10^{-6}$); (3) significant changes in the relationship between thymic parenchyma and thymic interstitial tissue with resulting increased organ complexity ($P = 0.03$); (4) severe reduction of thymocytes; and (5) other degenerative processes such as monocyte/macrophage infiltration of Hassall's bodies [15].

In addition, a combined clinical, radiologic, and pathologic study of 129 very low birth weight infants indicated a significant association between a markedly decreased thymic size at birth and subclinical chorioamnionitis [16].

Furthermore, De Felice *et al.* conducted a prospective study on 400 very low body weight preterm infants (mean birth weight: 1010 g) with mean gestational age of 27.5 weeks who survived >4 weeks. A 12.7% of these infants were subsequently developed bronchopulmonary dysplasia (BPD). Thymic size was measured on routine chest radiographs taken in the first 6 hours after birth and expressed as the ratio between the transverse diameter of the cardiothymic image at the level of the carina and that of the thorax (CT/T). A small thymus (CT/T <0.28) was observed in 94.1% of the infants with BPD and 2.9% of the infants without BPD [17].

Di Naro *et al.* also evaluated the impact of infections and preterm delivery on the size of fetal thymus. Their study included thirty-one women admitted with preterm labor and intact membranes between 24 and 32 weeks of gestation. Fetal thymus perimeter was measured sonographically, and amniocentesis for the microbiologic assessment of the amniotic cavity was performed. Placentas and umbilical cords were examined for the presence of chorioamnionitis/funisitis.

The prevalence of preterm delivery and intra-amniotic infection was 51.6% (16/31 women) and 32.3% (10/31 women), respectively. In all cases with intrauterine infection and in 23.8% of cases without intrauterine infection, the fetal thymus perimeter was below the 5th percentile for gestational age (10/10 women vs 5/21 women; $P < .01$).

Isolated histologic chorioamnionitis and funisitis were found in 22.6% and 25.8% of fetuses, respectively. The fetal thymus was below the 5th percentile for gestational age in 100%, 71.4%, and 12.5% of patients with histologic signs of funisitis and isolated chorioamnionitis and without histologic signs of infection, respectively [18].

In addition, Yinon *et al.* evaluated twenty-one pregnant women between 24 and 35 weeks of gestation with preterm premature rupture of membranes (PROM). Serial ultrasound examinations were performed during the latency period, and measurements of the fetal thymus size were obtained. Small thymus was defined as a thymus perimeter \leq 5th percentile according to a fetal thymus nomogram, which was based on measurements of 403 fetuses.

Diagnosis of chorioamnionitis was made using neonatal clinical parameters and histological examinations of the placentas. They found that 13 infants presented with thymus size below the 5th percentile. Among the 13 infants with small thymus, nine (69%) had clinical or histological findings consistent with the diagnosis of chorioamnionitis [19].

10. The likely causes of Ron's intracranial, retinal, and pulmonary bleeding and bleeding observed in other locations

At autopsy, Dr. Raven found that Ron had subdural, subarachnoid, and retinal bleeding. She alleged that Ron's bleeding was caused by blunt trauma to the head [5, 6]. Examination performed by the paramedics and the treating physicians at the hospital did not reveal evidence of injury caused by trauma on

Ron's body. In addition, the CT scan head exams performed on March 10th and 11th did not show skull fracture.

My review of the clinical data and pertinent medical studies to Ron's case reveals the following: 1) Ron's intracranial bleeding developed following his admission to the hospital (FAH) on March 10th; 2) The bleeding in Ron's case was not limited to the head region. He also had pulmonary bleeding and epidural and subdural bleeding over the cauda equina of the spinal cord. The bleeding in Ron's lungs was not reported by the medical examiner; 3) Ron had acute liver injury that causes bleeding; 4) Ron treated with high dose of epinephrine that causes bleeding; 5) Ron developed disseminated intravascular coagulation (DIC) and coagulation problems that lead to bleeding; and 6) Ron was suffering from a severe anemia that causes retinal bleeding.

10.1 Progress of Ron's intracranial bleeding

The CT head exams and the autopsy findings indicate that Ron's intracranial bleeding developed following his admission to the hospital (FAH) on March 10th. Ron's CT scan exam performed at 1 hour FAH did not show evidence of intracranial bleeding. His CT head exam taken at 25 FAH revealed the presence of subarchanoid without subdural bleeding. The subdural bleeding was observed only at autopsy (Table 25). The intracranial bleeding was fresh and tested negative with iron stain.

10.2 Pulmonary bleeding

Raven examined Ron's lungs at autopsy and stated that his lungs demonstrated atelectasis bilaterally. The pleural surfaces were smooth and glistening. Cut surface showed mildly congested, deep red to pink parenchyma with no evidence of natural disease or injury. There was no consolidation or enlargement of the air spaces. The weight of the right lung was 55 g. The weight of the left lung was also 55 g.

Raven examined the H & E stained sections of Ron's lungs microscopically and stated that the lung was congested and collapsed. She found intraalveolar macrophages (rare) and focal fat globule in vessel.

I also examined the two H & E stained sections of Ron's lungs microscopically that were obtained from the medical examiner office. I observed a significant bleeding in these sections, which was not reported by Raven. The bleeding is multifocal. Both airways and the alveoli contain fresh blood less than 24 hours old (Figures 1, 2, and 3).

The medical examiner reported that Ron's left and right lung had equal weight of 55 g. The left lung's weight should be about 15% less than the weight of the right lung. The left lung and the right lung consist of 2 lobes and 3 lobes, respectively. These data indicate that the bleeding in Ron's left lung is more severe than in his right lung.

Table 25. The progress of the intracranial bleeding observed at autopsy in Ron’s case

Date	Exam Type	Findings
3/10/07	CT Scan	<ul style="list-style-type: none"> • Diffuse anoxic brain lesion involving the supratentorial brain parenchyma.
3/11/07	CT Scan	<ul style="list-style-type: none"> • Subarachnoid hemorrhage appears to be present in the basilar cistern and in several of the sulci. • A small amount of parenchymal hemorrhage appears to be present in the left periventricular white matter.
3/12/07	Autopsy	<ul style="list-style-type: none"> • A small amount of subdural blood seen congealed but not adherent over the superior cerebral convexities. • Acute appearing subdural hemorrhage congealed over the base of the skull. • Diffuse subarachnoid hemorrhage. • Focal subarachnoid hemorrhage was seen on the right.

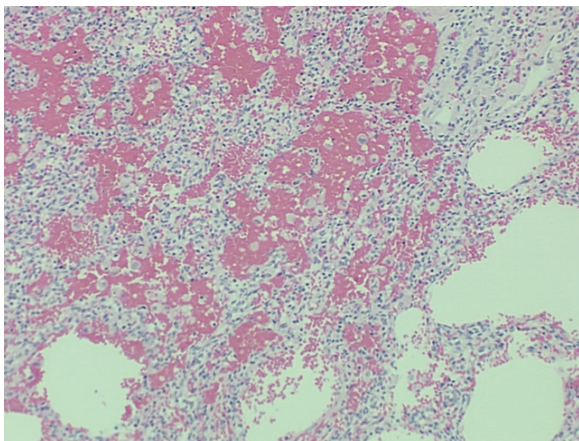


Figure 1. Shows multifocal bleeding in Ron’s lung (H & E, x=25)

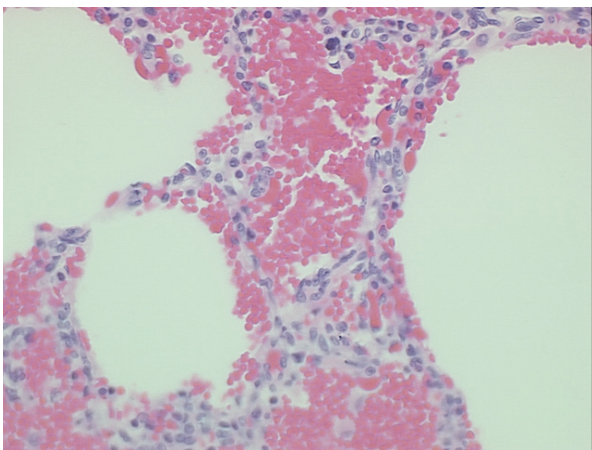


Figure 2. Shows fresh bleeding in the alveoli of Ron’s lung (H & E, x=63)

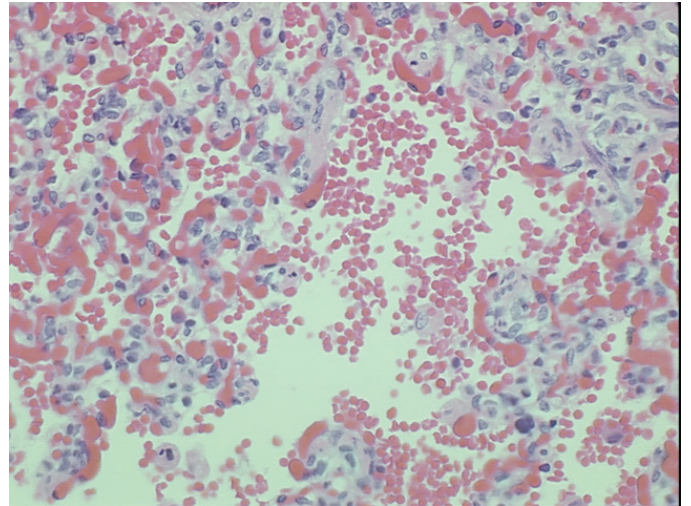


Figure 3. Shows fresh bleeding in the bronchioles of Ron’s lung (H & E, x=63)

10.3 High dose of epinephrine causes bleeding

The paramedics gave Ron 0.3 mL (IV) prior to 0800 on March 10th and high dose of epinephrine has shown to cause intracranial bleeding in some individuals. Epinephrine increases heart rate and blood pressure. Intracranial bleeding has been reported in some children and adults treated with high therapeutic doses of epinephrine [20-25]. For example, bleeding (intracerebral, subdural and/or subarachnoid hemorrhage) was reported as one of the serious adverse reactions of epinephrine, even when given to individuals at a low dosage level of 0.05 mg subcutaneously [20].

In addition, Horowitz *et al.* reported the development of acute cardiac arrest and fatal subarachnoid hemorrhage in an individual who suffered from allergic reaction and treated with epinephrine subcutaneously [21]. I also evaluated medical records and other medical evidence involving four cases of children who suffered from cardiac arrest and treated with high doses of epinephrine. These children also had intracranial bleeding and differential diagnosis identified epinephrine as important factor in causing bleeding in these children [23-26].

10.4 Acute liver injury causes bleeding problems

A blood analysis performed at about 3 hours FAH revealed that Ron had elevated serum levels of alkaline phosphatase, glutamic oxaloacetic transaminase (SGOT), and glutamic pyruvic transaminase (SGPT). His serum SGOT level was more than three times than the upper normal level (Table 16). These enzymes are associated with liver parenchymal cells and acute liver injury leads to the release of these enzymes to the blood. The likely cause of Ron’s liver damage was the precipitation of calcium phosphate.

Liver plays a central role in the clotting process. Injuries and diseases of the liver are usually associated with coagulation disorders due to multiple processes. These include reducing the synthesis of clotting and inhibitor factors, decreasing the clearance of activated factors, and producing quantitative and qualitative platelet defects. Some of these abnormalities may lead to hyperfibrinolysis and the acceleration of the intravascular coagulation process [27-33].

Most of the blood clotting factors is synthesized in the liver and a significant liver injury usually lead to blood clotting problem. Ron's prothrombin time (PT), activated partial thromboplastin time (APTT) and International normalized ratio (INR) values were elevated at 3 hour FAH (Table 17). His PT was 161% of the upper normal level. PT measures clotting factors II, V, VII, X and fibrinogen and these factors are synthesized in the liver.

Ron's platelet count at 40 minutes FAH was $220 \times 10^3/\mu\text{L}$ and increased by 156% as a result of the blood transfusions. However, his platelet count reduced by 52% within 11 hours (Table 21). These data indicate that Ron was suffering from disseminated intravascular coagulation (DIC) and coagulation problems.

10.5 Severe anemia leads to retinal bleeding in some individuals

Ron was admitted at 0806 on March 10th and his eye exam performed at 1245 revealed severe retinal hemorrhage in both eyes. No evidence of infection or trauma was observed. The medical examiner observed bilateral retinal and optic neuron hemorrhage. The bleeding tested negative with iron stain. I examined the H & E stained section of the retina and observed fresh bleeding.

Ron had at least three risk factors that can lead to retinal bleeding. These include acute liver injury, treatment with high dose of epinephrine, and severe anemia. A blood analysis performed at 40 minutes FAH showed that Ron had a red blood cell count of $2.37 \times 10^6/\mu\text{L}$, a hematocrit value of 19.4%, and a hemoglobin level of 6.2 g/dL. His red blood cell count, hematocrit value, and hemoglobin level were about 50% of normal (Table 21).

Some individuals with severe anemia have developed retinopathy and bleeding in the retina. For example, Asien *et al.* evaluated the occurrence of clinically apparent retinal changes in 35 anemic individuals and 35 age-and sex-matched healthy control individuals. Retinal photographs of all subjects were obtained and all vascular and extra vascular retinal lesions were recorded. No retinal abnormalities were observed in the control subjects.

Seven (20%) of the anemic individuals exhibited extra vascular lesions (flame-shaped hemorrhages, hard exudates, and cotton-wool spots). Within the group of anemic individuals, the mean hematocrit reading for those with extravascular lesions (N=7) was 24.7%. A significant negative correlation was determined between venous length and the level of hematocrit, thereby implying that retinal venous tortuosity is directly related to severity of anemia [34].

In addition, Carraro *et al.* conducted a cross-sectional study involved 226 individuals with anemia and/or thrombocytopenia to evaluate the incident of retinopathy among these individuals. A 47 healthy age-matched individuals were used as control. Retinopathy was observed in 28.3% of the anemic individuals as a whole.

The presence of fundus lesions was closely associated with severe anemia (Hb < 8 g/dL) and severe thrombocytopenia (PLT < $50 \times 10^3/\mu\text{L}$). Among the individuals with concomitant anemia and thrombocytopenia, the incidence of retinopathy was

38%. Retinal hemorrhages were found in all of the individuals with concomitant severe anemia and thrombocytopenia [35].

Furthermore, I have evaluated the medical records of three infants (2-4 months of age) who developed retinal bleeding as a result of severe anemia and vitamin K deficiency. The first infant had a hemoglobin level of 7.01 g/dL and a hematocrit value of 20.4%. The hemoglobin level and the hematocrit value of the second infant were 6.8 g/dL and 19.4%, respectively. The third infant had a hemoglobin level of 6.7 g/dL and a hematocrit value of 20.3% [36-38].

11. The likely causes of Ron's brain edema and necrosis observed at autopsy

At autopsy, Dr. Raven described Ron's brain as extremely friable and edematous. The cerebellum and brain stem demonstrated marked softening. The brain fixed weight was 590 g. Raven examined the H & E sections of Ron's brain microscopically and found early ischemic changes and necrosis in cerebrum, cerebellum, and medulla. She alleged that the changes observed in Ron's brain caused by blunt trauma to the head.

My review of the clinical data and the pertinent medical studies to Ron's case reveals the following: 1) The likely causes of Ron's brain edema were anoxia, acidosis, treatment with high doses of sodium bicarbonate, and irritation from bleeding. Most of his brain edema developed after his admission to the hospital. 2) The ischemic changes and necrosis observed in Ron's brain at autopsy were caused by anoxia, ischemia, treatment with high doses of sodium bicarbonate, and increased intracranial pressure. Below are descriptions of clinical and medical studies that support these conclusions.

11.1 Progression of Ron's brain edema and the likely causes

Clinical studies and the autopsy findings indicate that most of Ron's brain edema developed in the hospital. A CT scan exam performed at 1 hour following Ron's admission to the hospital (FAH) showed Ron's brain had anoxic changes and mild edema. His CT head exam taken at 25 FAH showed increased brain swelling and edema compared to the prior CT. The basilar cisterns were not well visualized and ventricles appear smaller than on the prior CT. At autopsy, Raven described Ron's brain as extremely friable and edematous.

Ron's brain edema was induced by anoxia, acidosis, treatment with high doses of sodium bicarbonate, and irritation resulted from bleeding. Ron's brain suffered from anoxia and ischemia for at least for 20 minutes on March 10th as result of his pulmonary cardiac arrest. Ron's father called 911 at 0726. Care flight arrived at the scene at 0739 and the paramedics brought Ron to the hospital at 0806.

In addition, the use of sodium bicarbonate at high therapeutic levels causes hypoxia and brain edema in children. Ron's blood pH was 7.13 at 3 hours FAH and rose to 7.50 with the treatment with high doses of sodium bicarbonate IV (Table 15). The treatment with high doses of sodium bicarbonate has caused anoxia and brain edema in infants [24, 25, 38, 39]. Fauci *et al.* reported that alkalinization of the blood with sodium bicarbonate increases the avidity of hemoglobin to bind oxygen, thus impairing the release of oxygen in peripheral tissues [40].

Ron had intracranial bleeding and blood causes irritation, edema, inflammation, and necrosis in the surrounding tissues [41-44]. For example, Mayer *et al.* performed paired consecutive CT and ^{99m}Tc -hexamethylpropylenamine oxime single-photon emission computed tomography (SPECT) scans during the acute (mean, 18 hours) and subacute (72 hours) phase of intracerebral hemorrhage (ICH) in 23 individuals.

Hematoma and edema volumes were traced and calculated from CT images. They found that the ICH volume (18 mL) did not change but the mean edema volume was increased by 36% (from 19 to 25 mL, $P < 0.0001$). Perilesional edema on CT always corresponded topographically with perfusion deficits on SPECT [42].

In addition, Mehdiratta *et al.* retrospectively reviewed prospectively-collected clinical and laboratory data from 23 consecutive individuals with acute spontaneous ICH. These individuals had a CT scan checked on admission and a follow-up CT scan 3 to 4 days afterward.

They measured hematoma and edema volumes on admission and follow-up scans, and calculated the relative edema volume to correct for hematoma volume. They used Spearman correlation coefficient to determine the association of various variables with relative perihematoma edema volume. They found that the median hematoma volume increased by approximately 28% from baseline to day 3 to 4. However, the relative edema volume almost doubled during this time period [43].

Furthermore, Gong *et al.* conducted study in rats to evaluate the development of inflammation and brain edema following the induction of intracerebral hemorrhage (ICH). Immunocytochemistry for polymorphonuclear leukocyte marker (myeloperoxidase, MPO), microglia marker (OX42) and intracellular adhesion molecule-1 (ICAM-1) was performed in control, and 1, 3, 7 and 10 days after the injection of 100 μL autologous blood in the right basal ganglia. They observed an inflammatory response in the brain after ICH. Infiltrating leukocytes and activated microglia may release cytotoxic mediators contributing to secondary brain injury and edema formation [44].

11.2 The likely causes of the ischemic changes and necrosis observed in Ron's brain

Raven examined the H & E stained sections of Ron's brain microscopically and found early ischemic changes and necrosis in the cerebrum, cerebellum, and medulla. I also examined the H & E stained sections of Ron's brain microscopically and observed ischemic changes and necrosis. The likely causes of these changes in the brain are anoxia, ischemia, edema and increased intracranial pressure (ICP), and irritation from bleeding.

Ron suffered from cardiopulmonary arrest for at least 20 minutes and his brain suffered from severe ischemia and anoxia. In addition, he was treated with high doses of sodium bicarbonate that increased his blood pH from 7.13 to 7.50. The treatment with high doses of sodium bicarbonate causes brain anoxia.

Stys stated that white matter of the brain and spinal cord is susceptible to anoxia and ischemia. Myelinated axons of the CNS are critically dependent on a continuous supply of energy largely generated through oxidative phosphorylation. Anoxia and ischemia lead to rapid energy depletion, failure of the Na^+ -

K^+ -ATPase, and accumulation of axoplasmic Na^+ through non-inactivating Na^+ channels, with concentrations approaching 100 mmol/L after 60 minutes of anoxia.

Ischemia and anoxia also cause severe K^+ depletion that results in large membrane depolarization. In addition, they lead to excessive accumulation of Ca^{2+} that activates various Ca^{2+} -dependent enzymes, such as calpain, phospholipases, and protein kinase C, resulting in irreversible injury [45].

In addition, Petty and Wettstein stated that brain and spinal cord white matter are vulnerable to the effects of ischemia. Reduction of the energy supply leads to a cascade of events that include depolarization, influx of Na^+ , and the subsequent reverse operation of the membrane protein the $\text{Na}^+/\text{Ca}^{2+}$ exchanger. These events ultimately lead to intracellular Ca^{2+} overload and irreversible axonal injury [46].

Dolinak *et al.* evaluated the relationship between hypoxia and the incidence of axonal injury in the brains of individuals died from cardio-respiratory arrest (17 cases) and status epilepticus (12 cases). Axonal damage was seen in 9/17 and 7/12 of the cases with cardiac arrest and status epilepticus, respectively, in most of whom there was also evidence of raised intracranial pressure (ICP). It is concluded that the great majority of axonal damage identified in cases dying after cardiac arrest and status epilepticus can be attributed to raised ICP and the vascular complications of internal herniation. In many cases there was an increase in expression of neuronal beta amyloid precursor protein [47].

In addition, Bell *et al.* investigated 70 brains of neonates died at birth with signs of asphyxia for beta-amyloid precursor protein (betaAPP) positivity. They found that positivity for betaAPP was present in neuronal soma in 52% of cases and, in axons, in 27% of cases, and was seen from as early as 25-weeks gestation. Axonal bulbs were clearly delineated by betaAPP positivity and were usually located in the cerebral white matter and internal capsule, and infrequently in the brain stem. They found that both neuronal karyorrhexes and white matter betaAPP positivity were significantly correlated with the features of birth asphyxia, particularly a history of seizures [48].

Furthermore, Kaur *et al.* evaluated material comprised sections from 28 brains showing evidence of cerebral hypoxia with no history of head injury to assess the possible role of hypoxia in the formation of axonal bulbs. These were subjected to microwave antigen retrieval and immunohistochemistry using monoclonal antibodies to beta amyloid precursor protein (beta APP), glial fibrillary acid protein (GFAP), and CD68-PGM1.

They found positive staining for beta APP present in 12 of 28 cases of hypoxia without history of head injury. They stated that the presence of axonal bulbs cannot necessarily be attributed to shearing forces alone [49].

Harrington *et al.* also evaluated brain tissues taken at autopsy from individuals for the presence of diffuse axonal injury (DAI). Twenty cases showed only evidence of neuronal hypoxic change with no history of head injury were studied. Eleven (55%) of these cases showed variable positive staining for betaAPP in a similar anatomical distribution to that previously described for DAI. They concluded that axonal injury cannot be assumed to result from mechanical injury alone [50].

12. The likely cause of the rib fracture observed at autopsy in Ron's case

Dr. Raven performed the autopsy on Ron's body on March 12, 2007 and reported that Ron had acute fracture of the left anterolateral 6th rib. She alleged that Ron's rib fracture caused by blunt trauma to the trunk [5, 6]. Examination of Ron's body by the paramedics and the treating physicians did not reveal the presence of injury caused by trauma.

Ron suffered from cardiopulmonary arrest on March 10th and his grandmother performed chest compressions prior to the arrival of the paramedics. The paramedics also performed cardiopulmonary resuscitation (CPR) on Ron. Single and multiple rib fractures have been observed in infants who received CPR following cardiac arrest.

For example, Dolinak evaluated the occurrence of cardiopulmonary resuscitation CPR-related rib fractures in 70 infant ranging in age from 2 weeks to 8 months, with no history or indications of injury. At autopsy, the parietal pleura of the thoracic cage was stripped and the ribs carefully examined for fracture. Subtle fractures of the anterolateral aspects of the ribs were discovered in 8 (11%) of the 70 cases.

In 7 of the 8 cases, multiple ribs were fractured (ranging up to 10 rib fractures), and in 5 of these cases, the rib fractures were bilateral. All of the rib fractures were subtle and had little if any associated blood extravasation. It is likely that these fractures were easily missed if the parietal pleura were not stripped [51]. The 6th rib fracture in Ron's case was also anterolateral.

In addition, Ron received chest compressions CPR then followed by standard (Std) CPR. The following medical studies show that individuals received active compression-decompression (ACD) CPR had more rib fractures than individuals received Std CPR. In addition, individuals received ACD-CPR followed by Std CPR had more rib fractures than individuals received only ACD-CPR or Std CPR.

1) Rabl *et al.* reviewed the autopsy protocols of 25 individuals who died after receiving Std CPR and 31 who died after receiving ACD-CPR, 15 of them preceded by Std CPR.

They found that 1) after Std CPR (n = 25) rib fractures were detected in 28%, sternal fractures in 16%, and no injuries in 68%; 2) after ACD-CPR (n = 16) rib fractures occurred in 68%, sternal fractures in 68% and no injuries in 25%; and 3) after ACD-CPR following Std CPR (n = 15) rib fractures were detected in 93%, sternal fractures in 93%, and no individual was without thoracic fracture [52].

2) Baubin *et al.* evaluated the autopsy of 15 individuals received ACD-CPR and 20 individuals Std CPR following cardiac arrest. They found that significantly more sternal fractures with ACD-CPR versus Std CPR (14/15 vs. 6/20; P < 0.005) and rib fractures (13/15 vs. 11/20; P < 0.05) [53].

13. Conclusions

My review of Ron James Douglas' medical records, autopsy report, testimonies of witnesses, and the pertinent medical studies to his case reveals the following:

1) Ron suffered from laryngeal spasm and cardiopulmonary arrest on March 10, 2007 due to severe hypocalcemia. He had a serum calcium level of 6.2 mg/dL. Hypocalcemia is defined as total blood calcium level below 9.0 mg/dL. The clinical manifestations of hypocalcaemia in children are neurological disorders such as seizures, respiratory disorders with possible laryngospasm, and/or severe cardiac disorders that may result in sudden death.

In addition, the increased level of phosphate in Ron's blood and tissues led to the binding of phosphate with calcium and the deposition of calcium phosphate in liver and kidneys, causing injuries to these organs. The likely causes of Ron's hypocalcemia were hypoparathyroidism and hyperphosphatemia. Ron developed hyperphosphatemia at 39 days following birth. However, his blood phosphate level was not measured during the period between December 27, 2006 and March 11, 2007. In addition, the functions of his parathyroid glands were not assessed.

2) Ron was also suffering from hemolytic anemia and his problem developed following birth. However, he was not monitored following his release from the hospital on January 10, 2007 to detect the problem.

3) The likely causes of Ron's involuted thymus were premature birth, chorioamnionitis, infections, and the treatment with corticosteroid.

4) Ron's intracranial bleeding developed following his admission to the hospital on March 10th. Ron also had pulmonary bleeding which was not reported by the medical examiner. The likely causes of Ron's bleeding were acute liver injury, treatment with high dose of epinephrine, and disseminated intravascular coagulation (DIC). In addition, Ron was suffering from severe anemia and retinal bleeding has been reported in individuals suffering from severe anemia.

5) The likely causes of Ron's brain edema were anoxia, acidosis, treatment with high doses of sodium bicarbonate, and irritation from bleeding. Most of his brain edema developed after his admission to the hospital on March 10th. Anoxia, ischemia, treatment with high doses of sodium bicarbonate, and the increase in the intracranial pressure caused the ischemic changes and necrosis observed in Ron's brain.

6) The likely cause of Ron acute fracture of the left anterolateral 6th rib was cardiopulmonary resuscitation (CPR) performed on March 10th. Ron received chest compressions prior to the arrival of the paramedics and then the paramedics performed CPR. Single and multiple rib fractures have been observed in infants who received CPR following cardiac arrest.

7) Raven's allegations that Ron was healthy baby prior to his cardiopulmonary arrest on March 10th and was killed by blunt trauma to the head and trunk are not supported by the clinical and the medical studies described in this report.

References

- [1] Ron James Douglas' medical records (November 17, 2006-January 10, 2007). Renown Regional Medical Center, Reno, Nevada.
- [2] Ron James Douglas' medical records (February 6-March 6, 2007). MED-School Associates North. Reno, Nevada.
- [3] Reno Fire Department. Incident report # 2007-0006742-000 concerning Ron James Douglas. March 10, 2007.
- [4] Ron James Douglas' medical records (March 10-12, 2007). Renown Regional Medical Center, Reno, Nevada.
- [5] Raven KP. Autopsy report in case of Ron James Douglas. Washoe County, Reno, Nevada. June 18, 2007.
- [6] Court hearing report. The state of Nevada, Plaintiff vs. Ronald Douglas, Senior, Defendant (Case No. RCR2007-036497). January 22, 2008.
- [7] Branchi M, Patriarca PL, Bordini P. Radioimmunologic analysis of calcitonin and parathyroid hormone in the study of calcium homeostasis in the newborn infant during the first days of life. *Pediatr Med Chir*. 1982 Nov-Dec;4(6):635–8.
- [8] Mallet E. Hypocalcemia in infants and children. *Rev Prat*. 1989 Apr 13;39(11):942–8.
- [9] De Holanda MR, De Melo AN. Prediction of etiology based on the clinical type of convulsion in the neonatal period. *Acta Cir Bras*. 2005; 20(Suppl 1):227–31.
- [10] Rowińska E. Two cases of epileptiform attacks due to hypocalcemia in a child with Hypoparathyroidism. *Neurol Neurochir Pol*. 1991 Jan-Feb;25(1):101–6.
- [11] Tseng UF, Shu SG, Chen CH, Chi CS. Transient neonatal hypoparathyroidism: report of four cases. *Acta Paediatr Taiwan*. 2001 Nov-Dec;42(6):359–62.
- [12] Halterman JS, Smith SA. Hypocalcemia and stridor: an unusual presentation of vitamin D-deficient rickets. *J Emerg Med*. 1998 Jan-Feb;16(1):41–3.
- [13] Hurley K, Baggs D. Hypocalcemic cardiac failure in the emergency department. *J Emerg Med*. 2005 Feb;28(2):155–9.
- [14] Lehmann G, Deisenhofer I, Ndrepepa G, Schmitt C. ECG changes in a 25-year-old woman with hypocalcemia due to hypoparathyroidism. Hypocalcemia mimicking acute myocardial infarction. *Chest*. 2000 Jul;118(1):260–2.
- [15] Toti P, De Felice C, Stumpo M, Schürfeld K, Di Leo L, Vatti R, Bianciardi G, Buonocore G, Seemayer TA, Luzi P. Acute thymic involution in fetuses and neonates with chorioamnionitis. *Hum Pathol*. 2000 Sep;31(9):1121–8.
- [16] De Felice C, Toti P, Santopietro R, Stumpo M, Pecciarini L, Bagnoli F. Small thymus in very low birth weight infants born to mothers with subclinical chorioamnionitis. *J Pediatr*. 1999 Sep;135(3):384–6.
- [17] De Felice C, Latini G, Del Vecchio A, Toti P, Bagnoli F, Petraglia F. Small thymus at birth: a predictive radiographic sign of bronchopulmonary dysplasia. *Pediatrics*. 2002 Aug;110(2 Pt 1):386–8.
- [18] Di Naro E, Cromi A, Ghezzi F, Raio L, Uccella S, D'Addario V, Loverro G. Fetal thymic involution: a sonographic marker of the fetal inflammatory response syndrome. *Am J Obstet Gynecol*. 2006 Jan; 194(1):153–9.
- [19] Yinon Y, Zalel Y, Weisz B, Mazaki-Tovi S, Sivan E, Schiff E, Achiron R. Fetal thymus size as a predictor of chorioamnionitis in women with preterm premature rupture of membranes. *Ultrasound Obstet Gynecol*. 2007 Jun;29(6):639–43.
- [20] Goodman & Gilman's. *The Pharmacological Basis of Therapeutics*. Editors: Hardman JG, Limbird LE, Molinoff, PB, Ruddon RW, and Gilman AG. 9th ed., 1996. McGraw-Hill, New York.
- [21] Horowitz BZ, Jadallah S, Derlet RW. Fatal intracranial bleeding associated with prehospital use of epinephrine. *Ann Emerg Med*. 1996 Dec;28(6):725–7.
- [22] Know O, Chung S, Lee K, Kim S. Spontaneous subarachnoid hemorrhage after intravenous epinephrine use for multiple bee stings. *Am J Emerg Med*. 2007 Feb;25(2):249–50.
- [23] Al-Bayati MA. Analysis of causes that led to Toddler Alexa Shearer's cardiac arrest and death in November 1999. *Medical Veritas* 2004 Apr.;1(1):86–117.
- [24] Al-Bayati MA. Analysis of Causes That Led to Baby Lucas Alejandro Mullenax-Mendez's Cardiac Arrest and Death in August-September of 2002. *Medical Veritas* 2004 Apr.;1(1):45–63.
- [25] Al-Bayati MA. Analysis of causes that led to subdural bleeding, skull and rib fractures, and death in the case of baby Aerial Buie. *Medical Veritas* 2007 Nov.;4(2):1452–69.
- [26] Al-Bayati MA. Analysis of causes that led to toddler Steven Young's respiratory arrest, intracranial and retinal bleeding, bronchopneumonia, peritonitis, and death. *Medical Veritas*, 2008 Nov.;5 (2):1775–96.
- [27] Amitrano L, Guardascione MA, Brancaccio V, Balzano A. Coagulation disorders in liver disease. *Semin Liver Dis*. 2002 Feb;22(1):83-96.
- [28] Denninger MH. Liver diseases and hemostasis. *Pathol Biol (Paris)*. 1999 Nov;47(9):1006–15.
- [29] Mammen EF. Coagulation abnormalities in liver disease. *Hematol Oncol Clin North Am*. 1992 Dec;6(6):1247–57.
- [30] Papadopoulos V, Filippou D, Manolis E, Mimidis K. Haemostasis impairment in patients with obstructive jaundice. *J Gastrointest Liver Dis*. 2007 Jun;16(2):177–86.
- [31] Peck-Radosavljevic M. Review article: coagulation disorders in chronic liver disease. *Aliment Pharmacol Ther*. 2007 Nov;26 Suppl 1:21-8.
- [32] Trotter JF. Coagulation abnormalities in patients who have liver disease. *Clin Liver Dis*. 2006 Aug;10(3):665-78.
- [33] Téllez-Avila FI, Chávez-Tapia NC, Torre-Delgadillo A. Coagulation disorders in cirrhosis. *Rev Invest Clin*. 2007 Mar-Apr;59(2):153-60.
- [34] Aisen ML, Bacon BR, Goodman AM, Chester EM. Retinal abnormalities associated with anemia. *Arch Ophthalmol*. 101(7):1049-52, 1983.
- [35] Carraro MC, Rossetti L, Gerli GC. Prevalence of retinopathy in patients with anemia or thrombocytopenia. *Eur J Haematol*. 67(4):238-44, 2001.
- [36] Al-Bayati MA. Analysis of causes that led to subdural bleeding and rib fractures in the case of baby Patrick Gorman. *Medical Veritas* 2006 Nov.;3(2):1019–40.
- [37] Al-Bayati MA. Analysis of causes that led to rib and skull fractures and intracranial bleeding in the case of the premature triplets Parneet, Sukhsaihaj, and Imaan. *Medical Veritas* 2008 Apr.; 5(1):1589–609.
- [38] Al-Bayati MA. Analysis of causes that led to baby Ryan's hemorrhagic pneumonia, cardiac arrest, intracranial bleeding, and retinal bleeding. *Medical Veritas* 2008 Nov.;5(2):1757–74.
- [39] Bureau MA, Begin R, Berthiaume Y, Shapcott D, Khoury K, and Gagnon N. Cerebral hypoxia from bicarbonate infusion in diabetic acidosis. *Journal of Pediatrics* 1980; 96:968-73.
- [40] Fauci AS, Braunwald E, Isselbacher KJ, Wilson, JD, Martin JB, Kasper DL, Hauser SL, and Longo DL. *Harrison's Principles of Internal Medicine*. McGraw-Hill Companies, Inc. New York USA, ed. 14, 1998.
- [41] Al-Bayati MA. Analysis of causes that led to bleeding, cardiac arrest, and death in the case of baby Nadine. *Medical Veritas* 2006 Nov.;3(2): 997–1012.
- [42] Mayer SA, Lignelli A, Fink ME, Kessler DB, Thomas CE, Swarup R, Van Heertum RL. Perilesional blood flow and edema formation in acute intracerebral hemorrhage: a SPECT study. *Stroke*. 1998 Sep;29(9):1791–8.
- [43] Mehdiratta M, Kumar S, Hackney D, Schlaug G, Selim M. Association between serum ferritin level and perihematoma edema volume in patients with spontaneous intracerebral hemorrhage. *Stroke*. 2008 Apr;39(4):1165–70. Epub 2008 Feb 21.
- [44] Gong C, Hoff JT, Keep RF. Acute inflammatory reaction following experimental intracerebral hemorrhage in rat. *Brain Res*. 2000 Jul 14;871(1):57–65.
- [45] Stys PK. Anoxic and ischemic injury of myelinated axons in CNS white matter: from mechanistic concepts to therapeutics. *J Cereb Blood Flow Metab*. 1998 Jan;18(1):2–25.
- [46] Petty MA, Wettstein JG. White matter ischaemia. *Brain Res Brain Res Rev*. 1999 Dec;31(1):58–64.
- [47] Dolinac D, Smith C, Graham DI. Global hypoxia per se is an unusual cause of axonal injury. *Acta Neuropathol*. 2000 Nov;100(5):553–60.
- [48] Bell JE, Becher JC, Wyatt B, Keeling JW, McIntosh N. Brain damage and axonal injury in a Scottish cohort of neonatal deaths. *Brain*. 2005 May;128(Pt 5):1070–81. Epub 2005 Feb 10.
- [49] Kaur B, Ruddy GN, Timperley WR. The possible role of hypoxia in the formation of axonal bulbs. *J Clin Pathol*. 1999 Mar;52(3):203–9.
- [50] Harrington D, Ruddy GN, Timperley WR. beta -amyloid precursor protein positive axonal bulbs may form in non-head-injured patients. *J Clin Forensic Med*. 2000 Mar;7(1):19–25.
- [51] Dolinac D. Rib fractures in infants due to cardiopulmonary resuscitation efforts. *Am J Forensic Med Pathol*. 2007 Jun;28(2):107–10.
- [52] Rabl W, Baubin M, Broinger G, Scheithauer R. Serious complications from active compression-decompression cardiopulmonary resuscitation. *Int J Legal Med*. 1996;109(2):84–9.
- [53] Baubin M, Sumann G, Rabl W, Eibl G, Wenzel V, Mair P. Increased frequency of thorax injuries with ACD-CPR. *Resuscitation*. 1999 Jun;41(1):33–8.