

Analysis of causes that led to bleeding, cardiac arrest, and death in the case of Baby Nadine

Mohammed Ali Al-Bayati, PhD, DABT, DABVT

Toxicologist & Pathologist

Toxi-Health International

150 Bloom Drive, Dixon, CA 95620

Phone: +1 707 678 4484 Fax: +1 707 678 8505

Email: maalbayati@toxi-health.com

Submitted: July 28, 2006 Accepted: August 14, 2006

Abstract

Ezsjörn Hahne was accused and convicted of killing his 40 day old daughter, Nadine, by shaking force (Shaking Baby Syndrome). Nadine suffered from cardiac arrest and died on September 16, 2004. The examination of her body and organs at autopsy and bone x-ray revealed no evidence of injuries caused by trauma. Ezsjörn was accused and convicted of killing Nadine based on the finding of old and new intracranial bleeding during autopsy.

My investigation of this case clearly indicates that Nadine died as a result of health problems and vitamin K deficiency that led to intracranial bleeding, edema of the brain, neurological problems, and cardiac arrest. Nadine was treated with three courses of antibiotics during her short life and had other predisposing factors for vitamin K deficiency. The evidence indicates that the intracranial bleeding occurred probably during the four weeks prior to Nadine's death.

Nadine was born at 33 weeks of gestation by caesarian section. Her mother suffered from pregnancy complications that led to the premature rupture of the fetal membranes. She also had a urinary tract infection that was treated with antibiotics for 10 days following delivery. Nadine suffered from infection, hemolytic jaundice, neurological problems, and retardation of growth. She gained only 625 g during her 40 days of life (15.6 g/day), which is about 58% below of the weight gain expected for an infant her age.

© Copyright 2006 Pearlblossom Private School, Inc.—Publishing Division. All rights reserved.

Keywords: antibiotic, bleeding, edema, gliosis of the brain, hemolytic anemia, jaundice, retardation of growth, premature labor, subdural beeding, shaken baby syndrome, vitamin K deficiency

1. Summary of the case and findings

Nadine is a Swedish, white female infant. She was born on August 7, 2004 at 33 weeks of gestation by caesarian section. Nadine's mother suffered from pregnancy complications that led to the premature rupture of the fetal membranes. She had a urinary tract infection and her urine culture tested positive for group B streptococcus (GBS). She was treated with antibiotics for 10 days following delivery.

Nadine suffered from cardiac arrest and died on September 16, 2004, at the age of 40 days. Her father, Ezsjörn Hahne was accused and convicted of killing Nadine by shaking force [Shaking Baby Syndrome (SBS)]. Examination of Nadine's body and organs at autopsy and bone x-ray revealed no evidence of injuries caused by trauma. Ezsjörn was accused and convicted of killing his daughter based on the finding of old and new intracranial bleeding during autopsy. Dr. Mario Verdicchio performed the autopsy on Nadine's body and Dr. Olof Flodmark served as expert witness for the prosecution. Both of them stated that Nadine died as a result of shaking force.

Two weeks prior to her death, Nadine suffered from apnea, hemolytic jaundice, sluggishness and slow response, and hypotonicity. She was hospitalized for five days and treated with antibiotics. In addition, Nadine stayed in the hospital for eight days following birth due to infection and jaundice and she was treated with antibiotics.

I was asked as a pathologist and toxicologist to review the medical evidence in Nadine's case and to provide my opinion

concerning the possible causes of illness and death in Nadine's case. I have over twenty years experience in the fields of toxicology and pathology. In addition, I have evaluated many cases of children similar to Nadine's case and have served as expert witness in these cases.

I reviewed the following documents pertinent to Nadine's case that were translated to English: (1) Nadine's medical records from August 7 to September 16, 2004. (2) Dr. Mario Verdicchio's report of December 8, 2004, describing his autopsy findings in Nadine's case. (3) Dr. Olof Flodmark's report of July 6, 2005, stating his opinion concerning the causes of Nadine's illness and death. In addition, I reviewed photographs of the brain (Figures 1 and 2) and Nadine's body taken during autopsy and the published medical literature pertinent to Nadine's case.

I have spent about 150 hours in evaluating the documents cited above and the pertinent medical literature and writing a detailed report in this case. I used differential diagnosis to identify the factual causes that led to Nadine's illness and death.

In this report, I described Nadine's medical records in Section 2 and the autopsy findings in Section 3. Section 4 contains my analysis of the causes of edema and gliosis observed in Nadine's brain during autopsy. Sections 5 and 6 describe the biomarkers of inflammation, infections, and growth retardation observed in Nadine's case. Section 7 contains my analysis of the causes that led to intracranial bleeding in Nadine's case. Lists of clinical data and medical facts that argue against the validity of Verdicchio and Flodmark's opinions given in Nad-

ine's case are presented in Sections 8 and 9, respectively. My conclusions are presented in Section 10.

Nadine suffered from hemolytic jaundice, infection, neurological problems, and retardation of growth. She gained only 625 g during her 40 days of life (15.6 g/day), which is about 58% below of the weight gain expected for an infant her age. The likely cause of the fresh and old bleeding observed during the autopsy in Nadine's brain, subdural space, and under the other membranes surrounding the brain is vitamin K deficiency. The evidence indicates that the intracranial bleeding occurred probably during the four weeks prior to Nadine's death on September 16, 2004.

Premature and full term infants who suffered from vitamin K deficiency also develop intracranial hemorrhage and bleeding in other locations. Nadine had several predisposing factors for vitamin K deficiency that included the following:

(a) She was treated with three courses of antibiotics during the first month of her life. Treatment of infants and older children with high therapeutic doses of antibiotics for a significant time causes vitamin K deficiency by inhibiting the growth of microflora in the intestine that synthesize vitamin K.

(b) Nadine was breast-fed during her life and breast milk contains a very low concentration of vitamin K. Furthermore, her mother was given antibiotic treatment for 10 days during the time when she breast-fed Nadine.

(c) Nadine was sick during her life and her illness caused her to eat less and her weight gain rate was 58% below normal for her age.

(d) Nadine suffered from hyperbilirubinemia and a high bilirubin level can induce vitamin K deficiency by causing cholestasis. These factors also led to vitamin K deficiency even in babies who were injected with one mg of vitamin K intramuscularly following birth.

The likely cause of the brain edema observed in Nadine's case was the bleeding, and the edema was probably formed during the 72 hours prior to Nadine's death. The primary cause of the gliosis observed in Nadine's brain was the bleeding in the brain. The gliosis was probably formed during the four weeks prior to Nadine's death. Nadine died as a result of acute neurological problems caused by bleeding and edema that led to cardiac arrest.

Verdicchio and Flodmark assumed that Nadine died as a result of shaking force (SBS) that occurred on September 16, 2004. I have found that the medical evidence pertinent to this case does not support their assumptions. It appears that they did not do differential diagnosis, consider the impact of Nadine's illness on her health, or perform the needed tests to rule out the involvement of vitamin K deficiency and sepsis in this case. Children suffering from vitamin K deficiency have increased plasma levels of K1 epoxide and noncarboxylated protein (PIVKA) and reduction in the levels of functioning vitamin K-dependent clotting factors. Their prothrombin time (PT) and activated partial thromboplastin time (APPT) are prolonged.

Furthermore, Flodmark did not mention in his report that the medical examiner observed mild to heavy gliosis in Nadine's brain. The clinical data presented in Section 4 of this report show that bleeding in the brain caused gliosis. Experimental studies showed that gliosis was observed in the brain one week following bleeding and lasted for at least three weeks. These data indicate that the gliosis in Nadine's brain started at least four weeks prior to her death. Furthermore, unconjugated bilirubin (UCB) can cross the brain barrier and cause brain damage (encephalopathy) and gliosis. Nadine suffered from hyperbilirubinemia following her birth on August 7, 2004 and during her hospitalization from September 2-7, 2004.

I have also questioned the validity of Flodmark's assumption that shaking-force caused the brain swelling observed during autopsy in Nadine's case. The clinical data presented in Section 4 of this report show that bleeding in the brain caused inflammation and edema and the fluid in the brain is increased with time for up to 72 hours post-bleeding. Fresh and old bleeding was observed in Nadine's brain during autopsy and bleeding should be considered as the likely cause of edema in this case.

In addition, Flodmark assumed that the cause of the old intracranial bleeding observed in Nadine's case was shaking-force that allegedly occurred on September 1st and 2nd. I have found that Flodmark's assumption is medically not valid. He did not perform differential diagnosis to rule out vitamin K deficiency, hemolytic anemia, infections, and developmental problems as causes for Nadine's illness and old bleeding. In addition, he did not provide any reason to explain Nadine's survival of the alleged double incidents of shaking on September 1st, 2nd and her death from the alleged single incident of shaking on September 16th.

In conclusion, my investigation in Nadine's case clearly indicates that Nadine died as a result of health problems and vitamin K deficiency that led to intracranial bleeding, neurological problems, and cardiac arrest. She was not injured and killed by her father, Ezbjörn Hahne, as alleged by Verdicchio and Flodmark.

2. Review of Nadine's medical records from birth to her cardiac arrest on September 16, 2004

2.1. Nadine's health problems during her first week of life and treatments given

Nadine is a Swedish, white female infant. She was born on August 7, 2004 at 33 weeks of gestation by caesarian section. Nadine's mother suffered from pregnancy complications that led to the premature rupture of the fetal membranes. Nadine's cardiotocogram (CTG) was abnormal. Nadine's mother had urinary tract infection and her urine culture tested positive for group B streptococcus (GBS). She was given antibiotic treatment for 10 days after delivery. Nadine's mother was 24-year-old at the time of delivery and she smoked during her pregnancy with Nadine [1].

Nadine was unstable at arrival but became stable and alert relatively quickly after cleaning and ventilation with mask and pouch for less than 2 minutes. Nadine's weight was 2.235 kg. Her length and head circumference were 48 cm and 30 cm, respectively.

Her respiratory and heart rates were normal. Her Apgar score at one minute was 9. She had a normal appearance except for birthmark (hemangioma) on the left side of the chest skin [1].

Blood analysis performed following birth revealed that Nadine had elevated C-reactive protein (CRP) level of 12 mg/L and her CRP level was increased to 79 mg/L (normal value = 6 mg/L). It indicates that the baby was suffering from infection and inflammation. Nadine was treated with antibiotics for a few days and her CRP level dropped to 28 mg/L on August 11, 2004 [1].

Blood analysis also revealed that Nadine's blood pyruvate kinase (PK) level was low. She suffered from hyperbilirubinaemia and received light treatment. Nadine and her mother were discharged from the hospital on August 16, 2004. Nadine was fed breast milk [1].

2.2 Nadine's symptoms and treatments given at the hospital on September 2-7, 2004

Nadine was admitted to Drottning Silvia's Children and youth hospital on September 2, 2004 at 0833 due to apnea (cessation of breathing), which occurred while at home. Prior to her hospitalization, Nadine was laying in her father's arms and started "rumbling" in the air passages. She sounded like she had mucus in her throat. Her parents tried to keep her alert and after a while she started breathing on her own and slowly regained color in her face and arms. Then, Nadine suddenly became pale. Her blood pressure and reactions to stimuli became low. She appeared sluggish and tired and her parents brought her to the hospital [1].

Nadine was examined in the hospital and she appeared sluggish and tired. Her oxygen blood saturation was 95% and she was given oxygen. Examination revealed that her fontanelles were soft. Her mouth, throat, ears, lymph nodes were normal. She had normal heart sound and her pulse was 160/min. Her abdomen felt soft and non-tender. Her temperature was 36.9 °C. Her weight was 2.62 kg. She gained 385 grams during her 26 days of life. Her weight gain rate was 14.8 g/day which is about 40% of the average normal weight gain rate for her age [1].

Nadine's food intake during the afternoon of September 2nd was low. She became more tired, developed a new wheezing sound, and suffered from hypotonia. She was pale and reacted badly to stimuli. Her plasma bilirubin level was 200 mg/L and she suffered from hemolytic anemia. Her blood bacterial culture revealed negative result [1].

Nadine was treated with two types of antibiotics by intravenous (IV) route on September 2nd and her treatment with antibiotics was terminated on September 7th. She was given 2.6 mL of benzylpenicillin (100 mg/mL) and 0.65 mL of Nebcina (Tobramycin) at 10 mg/mL per day. She was also treated via IV route with 5% Albumin (26 mL/2 hours) and 5% glucose solution (260 mL/20 hours) [1].

Nadine had abdominal ultrasound exam on September 5th and her kidneys appeared normal. On September 7th, Nadine's food intake was improved and she was fed 50-60 mL of breast milk. Her electrocardiogram (EKG) was normal. Her physician terminated her treatment with antibiotics and she was released from the hospital [1].

2.3 Nadine's cardiac arrest and events in connection with her death on September 16, 2004

On September 16, 2004, Nadine was traveling with her father in his car when she suddenly became pale, started vomiting and then stopped breathing. Her father started resuscitation and called for help. When the ambulance arrived, Nadine had neither spontaneous breathing nor heart function. Resuscitation efforts were fruitless. She was pronounced dead on September 16, 2004. Blood analysis revealed that Nadine was anemic. Her hemoglobin level was 85 g/L which is 35% below normal average value for age (130 g/L). She had elevated blood C-reactive protein (CRP) level of 13 mg/L which is twice the normal expected level of 6 mg/L. Nadine's blood culture and urine culture showed growth of non-coagulate staphylococci and Gram-negative bacteria, respectively [1].

Autopsy was performed on Nadine's body on September 17th. Prior to autopsy, a physician operated on Nadine's body and removed her heart valves [1]. It seems that blood sample from Nadine's body was not taken prior to removing her heart valves or her autopsy to do standard hematology tests to check for sepsis, vitamin K deficiency, hemolytic anemia, and jaundice.

3. The autopsy and pathology findings in Nadine's case

Dr. Mario Verdicchio performed the autopsy on Nadine's body on September 17, 2004. The autopsy report was signed by Drs Mario Verdicchio and Adam Berkowicz on December 8, 2004. Nadine's weight and length were 2.86 kg and 53 cm, respectively. Examination of Nadine's body and organs and bone x-ray revealed no evidence of injuries caused by trauma. Muscle sample was analyzed for the presence of illicit drugs and showed negative result [2]. The medical examiner observed the followings abnormal lesions in Nadine's meningeal membranes, brain, and lungs:

1. Nadine's brain was severely swollen and soft. The formalin-fixed brain's weight was 370 g.
2. Gross and microscopic examination of the dura mater and other membranes covering the brain and the brain revealed bleeding of varying ages (fresh and old) present in many locations. Figures 1 and 2 show the intensity and the distribution of the fresh and old bleeding on the surfaces of Nadine's brain observed at the time of autopsy. Microscopic examination of H & E stained tissue sections of the bleeding areas in the brain and the membranes revealed the presence of abundant pigment-loaded macrophages and hemosiderin and iron.
3. Microscopic examination of H & E stained tissue sections of the brain revealed the presence of mild to heavy reactive gliosis in the cortex. Immunohistochemical staining for glial fibrillary acidic protein (GFAP) showed the gliosis was continued deeper into the underlying white substance.
4. Microscopic examination of H & E stained tissue sections of the lungs revealed the presence of inhaled stomach content.

The medical examiner stated that: (1) the subdural bleeding and the bleeding in the brain (new and old) was caused by blunt shaking force; (2) the new bleeding has appeared in direct conjunction with death; (3) the older injuries have appeared at least one week prior to death, which also caused by similar trauma; (4) inhalation of the stomach contents was resulted from injuries; (5) the findings speak strongly for that death was caused by injuries and the collected picture speaks strongly for death being caused by another person.

My review of the clinical data, autopsy findings, and the pertinent medical literature to this case revealed that the medical examiner did not do differential diagnosis in this case. In addition, it seems that he did not take blood sample from Nadine's body to do standard hematology tests to check for sepsis, vitamin K deficiency, hemolytic anemia, and jaundice.

I have found that Verdicchio's conclusions are not supported by medical facts. Lesions in the brain, bleeding, and death in Nadine's case were caused by health problems and adverse reactions to antibiotics. These include jaundice, hemolytic anemia, infection, vitamin K deficiency, and development problem. Detailed descriptions of the medical data and scientific studies that explain the factual causes of injuries and death in this case are described in Sections 4-7 below. In addition, I presented a list of clinical data and medical facts that argue against the validity of Verdicchio's conclusions.

4. The likely causes of the edema and gliosis of the brain observed in Nadine's case

Nadine's brain was severely swollen and soft. The gross and microscopic examination of the dura mater and other membranes covering the brain and the brain revealed the followings: (1) Bleeding of varying ages (fresh and old) present in many locations. (2) The presence of abundant pigment-loaded macrophages and hemosiderin and iron. (3) The presence of mild to heavy reactive gliosis in the cortex of the brain, which continued deeper into the underlying white substance.

The presence of old blood, hemosiderin, and gliosis indicates that Nadine suffered from chronic bleeding in the subdural space and the brain and the initial bleeding was probably started four weeks prior to her death. Blood and blood products cause irritation that result in cell death, edema and gliosis. In addition, Nadine suffered from severe jaundice and unconjugated bilirubin can cross blood brain barrier and causes brain damage and gliosis. Below is a description of the medical data and clinical studies that explain the pathogenesis of the brain lesions observed in Nadine's case.

4.1 Edema of the brain

Nadine's brain was severely swollen and soft. The main cause of the edema in the brain is probably the bleeding. Studies on intracerebral hemorrhage (ICH) in human and experimental animals indicate that bleeding causes inflammation and brain edema. These studies also show that significant amount of fluid was detected at 24 hours post ICH in the tissue surrounding the ICH and stayed for 7 days. The results of some of these studies are described below.

1. Mayer *et al.* performed paired consecutive CT and 99mTc-hexamethylpropylenamine oxime single-photon emission computed tomography (SPECT) scans during the acute (mean, 18 hours) and subacute (mean, 72 hours) phase of intracerebral hemorrhage (ICH) in 23 individuals. Hematoma and edema volumes were traced and calculated from CT images. They found that the ICH volume (18 mL) did not change but the mean edema volume was increased by 36% (from 19 to 25 mL, $P < 0.0001$). Perilesional edema on CT always corresponded topographically with perfusion deficits on SPECT [3].

2. Yang *et al.* investigated the time course for the formation and resolution of brain edema after the induction of intracerebral hemorrhage (ICH) in rats. Anesthetized adult rats received a sterile injection of 100 μ L of autologous blood into the caudate nucleus. Water and ion contents were measured immediately, at 4 and 12 hours and daily to Day 7 (10 time points, six rats at each time) after experimental ICH. The water content of the ipsilateral basal ganglia increased progressively ($p < 0.002$) over the first 24 hours, then remained constant until after Day 5, when the edema began to resolve. Edema was most severe in the tissue immediately surrounding the hemorrhage; however, it was also present in the ipsilateral cortex, the contralateral cortex, and the basal ganglia [4].

3. Patel *et al.* induced intracranial hemorrhage in rat by the injection of 100 or 200 μ L of blood into the subdural space. Brain edema was measured using the wet/dry weight method. They detected significant increases in water content of the cerebral cortex of the brain at 24 hours after subdural bleeding as compared with those of the control animals (control: 0.1 ± 0.1 g/g dry weight; 200 μ L: 0.8 ± 0.3 g/g dry weight; $p < 0.001$) [5].

4. Xi *et al.* injected saline, packed red blood cells (RBCs), or lysed RBCs into the right caudate nucleus of pentobarbital-anesthetized Sprague-Dawley rats. Sham injections served as controls. Regional cerebral blood flow, brain water and ion contents, blood-brain barrier integrity, and plasma volume were measured. Intraparenchymal infusion of lysed RBCs caused severe brain edema by the first day. Blood-brain barrier permeability increased during the first day after infusion of lysed RBCs (a 3-fold increase) and 3 days after infusion of packed RBCs (a 4-fold increase) [6].

5. Gong *et al.* conducted study in rats to evaluate the development of brain edema following the induction of intracerebral hemorrhage (ICH). Immunocytochemistry for polymorphonuclear leukocyte marker (myeloperoxidase, MPO), microglia marker (OX42) and intracellular adhesion molecule-1 (ICAM-1) was performed in control, and 1, 3, 7 and 10 days after the injection of 100 μ L autologous blood in the right basal ganglia. They observed an inflammatory response in the brain after ICH. Infiltrating leukocytes and activated microglia may release cytotoxic mediators contributing to secondary brain injury and edema formation [7].

4.2 Gliosis of the brain

Nadine died on September 16, 2004 and microscopic examination of H & E stained tissue sections of the brain revealed the presence of mild to heavy reactive gliosis in the cortex and white matter [2]. Gliosis is the proliferation of fibrillary astrocytes with the formation of many glial fibers [8].

Experimental studies showed that bleeding in the brain induced gliosis. Gliosis was observed one week following the injection of the blood into the brain and lasted for at least three weeks. The bleeding in Nadine's brain was fresh and old. The old bleeding was probably one-week old. These data indicate that the gliosis in Nadine's brain was probably started four weeks prior to her death.

Furthermore, unconjugated bilirubin (UCB) can cross the brain barrier and causes brain damage (encephalopathy) and gliosis. Nadine suffered from hyperbilirubinemia following her birth on August 7, 2004 and during her hospitalization in September 2-7, 2004. Below are clinical studies that show bleeding and unconjugated bilirubin caused inflammation and gliosis of the brain.

4.2.1 Bleeding in the brain induces gliosis

The followings are experimental studies that show bleeding in the brain induced cell death and gliosis:

1. Kowianski *et al.* and Karwacki and Kowianski found that experimentally induced hemorrhage in the brain of rat caused programmed cell death and acted as a strong stimulus for both microglial and astroglial activations. They produced the intracerebral hematoma by injecting 100 μ L of autologous arterial blood into the striatum of a rat. The animals' brains were removed at 1, 3, 7, 14 and 21 days after production of the hematoma. The terminal deoxynucleotidyl transferase-mediated deoxyuridine triphosphate nick-end labeling (TUNEL) method was used to detect DNA fragmentation and TUNEL-positive cells. Microglial-macrophage lineage cells were immunocytochemically stained with antibodies OX42, OX6 and ED1. The astrocytic population was studied by means of anti-GFAP staining.

TUNEL-positive cells were found on the first day of observation and were present for three weeks after hematoma production. Changes in cellular morphology and intensity of staining were time-dependent reactions in both microglial and astroglial cells.

Strong activation of microglial-macrophage lineage cells revealed with OX6-and OX42-immunoreactivity started during the first postoperative day. The complete pattern of activation for ED1-immunoreactivity was observed from the third postoperative day. At this stage, numerous phagocytic macrophages started to appear in the perihematoma region.

Morphological changes were most intensive during the second postoperative week. The astroglial (anti-GFAP) reaction was observed after the third postoperative day and proceeded less dynamically. The glial reaction gradually stopped but not completely during the period of observation. The early occurrence of glial activation, pattern of morphological changes and

characteristic sequence of antigens expression indicate a very intense type of glial reaction [9, 10].

2. Koeppen *et al.* injected 100 μ L of autologous whole blood intracerebrally in adult rabbits. They found that the extravasation of blood elicits a cellular reaction in the adjacent surviving tissue where the lesion activates resident microglia and attracts many more phagocytes from the blood stream. The cellular responses to the injections were studied by iron histochemistry and immunocytochemistry for ferritin, the ferritin repressor protein (FRP), the glial fibrillary acidic protein (GFAP), and the complement receptor CR3. Conversion to hemosiderin began at 5 days after the injection of blood. The lesions caused initial destruction of astrocytes in the perifocal zone as judged by GFAP- and FRP-immunoreactivity. However, at 5 days, astrocytic processes reentered the perifocal zone and intermingled with microglia and macrophages [11].

4.2.2 Bilirubin-induced brain damage and gliosis

Nadine suffered from hyperbilirubinemia following birth on August 7, 2004 and she received light treatment. The serum levels of bilirubin were not given. On September 2, 2004, Nadine suffered from apnea and she was admitted to Östra Hospital. Blood analysis revealed that her serum bilirubin level was 200 mg/L (342 μ mol/L) and she suffered from hemolytic anemia and hyperbilirubinemia.

Suchonska *et al.* measured the concentrations of bilirubin in the umbilical and venous blood of 187 full-term newborns. The umbilical blood was taken immediately after delivery and the venous blood on the 3rd day of life. Bilirubin values lower than 129 mg/L were considered physiological and hyperbilirubinemia was recognized when the concentration of bilirubin was over 129 mg/L [12].

Bilirubin is one of the products of heme catabolism. It is a weak acid and not water soluble or readily excreted at pH 7.40 without conjugation with glucuronic acid in the liver. It can penetrate the blood brain barrier and causes neurological problems. Hyperbilirubinemia is capable of producing a spectrum of neurological dysfunction in the newborn, ranging from transient mild encephalopathy to permanent severe neurological impairment secondary to neuronal necrosis [13].

Unconjugated bilirubin (UCB) encephalopathy is a condition resulting from the impairment of several cellular functions in the brain of severely jaundiced infants [14]. Sepsis and the use of antibiotics enhance the toxicity of bilirubin. Antibiotic competes with UCB in binding with serum albumin and allow more unconjugated bilirubin to pass the blood brain barrier and deposit in the brain. Nadine was treated with three courses of antibiotics during the periods when she was suffering from jaundice. Below are the results of in vivo and in vitro medical studies that show the toxicity of bilirubin to the nervous tissue.

1. Oktay *et al.* evaluated the relationship between encephalopathy and serum free bilirubin levels in 83 newborn infants (40 premature, 43 mature) with unconjugated hyperbilirubinemia. The serum free bilirubin level exceeded 1 mg/L in 13 infants, and 12 of them showed signs of encephalopathy [15].

2. Ebbesen *et al.* conducted study included thirty-two infants born alive at term or near-term and developed extreme hyperbilirubinaemia. The maximum total serum bilirubin concentration (TSB) was 492 (385-689) $\mu\text{mol/L}$. Twelve infants had signs and symptoms of central nervous system involvement [16].

3. Kumral *et al.* evaluated the toxic effect of hyperbilirubinemic serum of infant on murine astrocytes. They found that hyperbilirubinemic serum induces cytotoxicity and apoptotic astrocyte death in a concentration- and time-dependent manner. In this study, heat-inactivated patient serum was added to astrocyte cultures at different concentrations varying from 1 to 20%, and cultures were incubated for 24, 48, and 72 h. Sera from healthy infants without hyperbilirubinemia were used as controls. Cytotoxicity was evaluated according to the release of lactate dehydrogenase in the culture medium. Apoptotic cell death was determined by anti-single-strand DNA immunostaining [17].

4. Fernandes *et al.* found that unconjugated bilirubin (UCB) activated astrocytes in cultures and caused the production of cytokines which is toxic to the nerve cells. These data indicate that during neonatal hyperbilirubinaemia, astrocytes activated by unconjugated bilirubin (UCB) may contribute to brain toxicity through the production of cytokines [14].

5. Gordo *et al.* found that microglial cells were activated by UCB and produced cytokines tumor necrosis factor (TNF)-alpha, interleukin (IL)-1beta, and IL-6 in a concentration-dependent manner. In addition, UCB triggered extracellular accumulation of glutamate and an increased cell death by apoptosis and necrosis.

These results indicate that UCB is toxic to microglial cells and point to microglia as an important target of UCB in the central nervous system. Collectively, these data indicate that microglia may play an important role in the pathogenesis of encephalopathy during severe hyperbilirubinemia [18].

4.2.3 Interaction between bilirubin and sepsis in causing brain damage

The clinical data described above show that Nadine suffered from jaundice and infection. Her elevated serum CRP level of 79 mg/L indicates that she suffered from sepsis. Below is the result of a study that shows the synergistic action between bilirubin and sepsis in causing inflammation in the brain.

1. Falcao *et al.* investigated cell death, glutamate efflux, and inflammatory cytokine dynamics after exposure of astrocytes at different stages of differentiation to clinically relevant concentrations of unconjugated bilirubin UCB and/or lipopolysaccharide (LPS). They found that younger astrocytes were more prone to UCB-induced cell death, glutamate efflux, and inflammatory response than older ones. Furthermore, in immature cells, LPS exacerbated UCB effects, such as cell death by necrosis. These data explain the increased susceptibility of premature newborns to UCB deleterious effects, namely when associated with sepsis [19].

5. Biomarkers of inflammation and infection observed in Nadine's case

Liver produces C-reactive protein (CRP) and the levels of CRP in the blood are increased during episodes of inflammation and infections. In the clinical setting, the CRP levels in serum of children and adults are measured to monitor the severity of the inflammation and infections and the effectiveness of antibiotics to cure infections [20-29]. The average normal level of CRP in serum of healthy newborns is about 5 mg/L [30].

Nadine was born on August 7, 2004 and her CRP level in serum on August 8th was 12 mg/L, which is twice the average normal value. On the following day, Nadine's CRP level in serum was increased to 79 mg/L (15 times of the average normal value). Nadine's CRP levels indicate that she was suffering from acute inflammation and infections. Nadine was treated with antibiotic for a few days and her CRP level was dropped to 28 mg/L on August 11, 2004. During that time, Nadine suffered from jaundice and her mother tested positive for Group B streptococcus infection. Nadine's mother was given antibiotic treatment for 10 days after delivery.

Furthermore, Nadine was hospitalized on September 2, 2004 and she was discharged on September 7th. She suffered from apnea, hemolytic anemia, and jaundice. She was treated with antibiotics for five days. However, her CRP levels in serum were not measured to monitor inflammation, infection, and Nadine's response to her treatment with antibiotics.

On September 16, 2004, Nadine suffered from cardiac arrest and died. Her blood analysis revealed that she had elevated CRP level of 13 mg/L and low hemoglobin level of 85 g/L. Blood and urine bacterial cultures showed growth of non-coagulate staphylococci and Gram-negative bacteria, respectively. Nadine's CRP level and the results of the bacterial cultures indicate that Nadine also suffered from infections on September 16, 2004.

Below are descriptions of clinical studies that show the usefulness and the sensitivity of CRP measurements in monitoring inflammation and infection in children and adults. These studies also confirm that Nadine suffered from inflammation and infection during her first week of the life and prior to her death.

1. Benitz *et al.* conducted study in a regional intensive care nursery and two community intensive care nurseries to evaluate serial serum C-reactive protein (CRP) levels for diagnosis of neonatal infection. CRP levels were determined at the initial evaluation and on each of the next two mornings. Two CRP levels <10 mg/L obtained 24 hours apart, 8 to 48 hours after presentation, indicate that bacterial infection is unlikely.

Sepsis was suspected within the first 3 days after birth in 1002 infants (early-onset) and on 184 occasions in 134 older infants (late-onset). There were 20 early-onset and 53 late-onset episodes of proven sepsis, and 74 early-onset and 12 late-onset episodes of probable sepsis.

They found that three serial serum CRP levels had sensitivities of 97.8% and 98.1% for proven or probable sepsis and 88.9% and 97.5% for proven sepsis in early-onset and late-onset episodes, respectively. The negative predictive values for CRP x 3 were 99.7% and 98.7% for both proven or probable sepsis and for proven sepsis in early-onset and late-onset epi-

sodes, respectively. They concluded that serial CRP levels are useful in the diagnostic evaluation of neonates with suspected infection [21].

2. Nuntnarumit *et al.* evaluated the usefulness of serum C-reactive protein (CRP) measurements in the diagnostic evaluation of neonates with suspected infection.

They conducted a prospective observational study included 76 newborn infants, aged > 3 days and diagnosed with clinical sepsis. CRP levels in serum were measured initially at the time of septic work-up and at 24-48 hours later. Investigations for infection included Complete Blood Count (CBC), blood culture and urine culture. Radiological study and lumbar puncture were performed if clinically indicated.

Of 76 newborn infants with 90 episodes of clinical sepsis, there were 24 episodes of proven sepsis, 11 episodes of localized infection with negative culture, 18 episodes of probable infection and 37 episodes of no infection. They found that serial CRP had better predictive values than those of Complete Blood Count (CBC). The sensitivity, specificity, positive predictive value, and negative predictive value of CRP for proven sepsis and localized infection at cutoff point ≥ 5 mg/L were 100 per cent, 94 per cent, 91.6 per cent and 100 per cent respectively. In this study, serial CRP showed very high predictive values for diagnosis of neonatal sepsis and was better than those of leukocyte indices of CBC [25].

3. Pourcyrous *et al.* assessed the C-reactive protein (CRP) response of 491 infants on 691 occasions of suspected infection and found it very useful in monitoring infections and inflammations. CRP levels were measured initially and twice again at 12-hour intervals. CRP responses were correlated with four designated clinical groups: (1) positive blood or cerebrospinal fluid cultures ($n = 190$); (2) negative blood culture-definite infection (necrotizing enterocolitis stages 2 and 3, pneumonia, subcutaneous abscess) ($n = 52$); (3) negative blood culture-possible infection (antenatal risk factors, meconium aspiration, positive urine group B streptococcus antigen, necrotizing enterocolitis stage 1, febrile infants) ($n = 287$); and (4) negative blood culture-no infection (respiratory distress syndrome, transient tachypnea of the newborn, patent ductus arteriosus, tissue trauma) ($n = 160$) [27].

In the 187 of the blood cultures that were positive. A single organism was recovered from 174 of these; two organisms from 13. Among the single-organism cultures, 50 (29%) were Gram-negative, 120 (69%) were Gram-positive, and 4 (2%) were budding yeasts. CRP levels were elevated in various groups as follows: in the positive blood culture group (by organism), Gram-negative rods, 92% (46/50); group B streptococcus, 92% (12/13); Staphylococcus aureus, 89% (8/9); group D streptococcus, 71% (10/14); Streptococcus viridans, 60% (6/10); Staphylococcus epidermidis, 55% (40/73). In the negative blood culture-definite infection group, CRP levels were abnormal in 88%; in the negative culture-possible infection group, CRP was elevated in 33%; and in the negative blood culture-no infection group, CRP was elevated in 9% [27].

4. Romagnoli *et al.* conducted a prospective study in 39 premature neonates (25-34 weeks gestational age) with signs and

symptoms of suspected sepsis. The C-reactive protein (CRP) was measured at 0-24 h after enrolment. 25 newborns with sepsis (blood culture positive), seven with pneumonia (positive results on broncho-alveolar lavage fluid culture and characteristic chest radiography) and seven with necrotizing enterocolitis (NEC) (characteristic intestinal and radiological signs according to the criteria of Bell *et al.*). A group of 20 healthy preterm neonates represented control subjects [29].

On admission, higher CRP was observed in neonates with sepsis: CRP (median 22 mg/L, range 4-80 mg/L); pneumonia: CRP (median 10 mg/L, range 8-33 mg/L) and NEC: CRP (median 3 mg/L, range 2.8-8 mg/L) as compared to controls CRP median < 2 mg/L). Preterm neonates with sepsis, pneumonia or necrotizing enterocolitis showed increased C-reactive protein levels [29].

5. Ehl *et al.* evaluated one hundred seventy-six newborns with birth weights of greater than 1500 g who had suspected bacterial infection. Serum concentrations of C-reactive protein (CRP) were determined 24 to 48 hours after the first dose of antibiotics. If CRP levels were less than 10 mg/L, infants were considered unlikely to be infected, and the antibiotic treatment was stopped using CRP as the single decision criterion in 84 of 94 newborns (group 1). Infants with CRP levels of 10 mg/L or greater were considered likely to be infected and randomized to two study groups. In 38 of 39 neonates (group 2a), CRP was determined daily, and antibiotic therapy was discontinued as soon as CRP returned to less than 10 mg/L. Forty-three neonates with likely infection (group 2b) were treated for at least 5 days, and relapse rates of bacterial infections were compared between groups 2a and 2b.

Within the 4-week follow-up period, one infant in group 1 and no infant in group 2a received a second course of antibiotics for bacterial infection. CRP levels of less than 10 mg/L determined later than 24 hours after beginning the antibiotic treatment thus correctly identified 120 of 121 infants as not needing further antibiotics. This corresponds to a negative predictive value with respect to further treatment of 99% (95% confidence interval, 95.4% to 99.9%) [22].

6. Jankovic *et al.* monitored changes in serum C-reactive protein (CRP) concentrations in neonates with proven neonatal sepsis in response to initial antibiotic therapy. They found measurement of serum CRP concentration is useful for diagnosis of severe neonatal sepsis. In this study, neonates received ampicillin and gentamycin/or amikacin (during the first week of life), while infants older than 7 days of life were given combination of cloxacillin and aminoglycosides. In patients with late neonatal sepsis who also had meningitis, cloxacillin was substituted with ampicillin. Serum concentration of CRP was measured before the treatment (CRP0), and during the first (CRP1) and second (CRP2) day of empiric therapy. The interval between sampling was from 12 to 24 hours.

In their study all isolated bacterial strains were comparable in their ability to activate systemic inflammatory response and CRP production [23].

7. Philip and Mills treated 425 infants with antibiotics based on an increased level of C-reactive protein (CRP) >10 mg/L and

discontinuation of antibiotic treatment was primarily based on return to normal of the CRP. Peak CRP primarily determined the duration of antibiotic treatment, with the mean peak CRP rising from 28 mg/L in those treated for 3 days, to 3.8, 4.3, 8.4, 8.9, and 137 mg/L in those treated for 4, 5, 6, 7, or >7 days, respectively. The mean duration of treatment was 3.1 days [26].

6. The impact of Nadine's chronic illness of her growth rate and organs' weight

Nadine's growth rate was significantly lower than the average growth rate of premature infant in her age. Her weight gain rate was about 58% below average normal. Her organs' weights for brain, heart, liver, right lung, and kidneys were also lower than normal weights for her age. These data indicate that Nadine was chronically ill.

6.1 Nadine's body weight and growth rate

Nadine was born at 33 weeks of gestation on August 7, 2004. Her birth weight was 2.235 kg (4.9 lbs). She died on September 16, 2004 and her weight was 2.860 kg (6.3 lbs). She gained only 625 g (22 ounces) during her 40 days of life and her weight gain rate was 15.6 g (0.55 ounces) per day (Table 1). She should have gained at least 38 g (1.3 ounces) per day based on the data presented in Table 2, which show the average weight gains for infants born at 32 to 40 weeks of gestation. These data indicate that Nadine's weight gain rate was 58% below the normal gain of infants in her age.

Nadine suffered from severe growth retardation because she suffered from severe jaundice, anemia (hemoglobin level of 85 g/L), infection, bleeding, and inflammation of the brain that reduced her food intake. For example, Tarcan *et al.* conducted prospective study involved 115 infants >48 hours old who were admitted with jaundice and had unconjugated bilirubin levels >120 mg/L. Twenty-eight (33%) of the 86 newborns with idiopathic hyperbilirubinemia in the study exhibited severe weight loss [31].

Table 1. Nadine's weight gain rates at various intervals during her life

Period	Duration (days)	Weight gain (g) ¹	Rate (g/day)
Aug. 7-Sept. 2, 2004	26	385	14.8
Sept. 2-16, 2004	14	240	17.1
Aug. 7-Sept. 16, 2004	40	625	15.6

¹Nadine weights were 2.235 kg on August 7; 2.62 kg on September 2; and 2.860 kg on September 16, 2004 [1, 2].

Table 2. Weight gain rates of premature and full term infants died at one month after birth¹

Gestation period (weeks)	Birth Weight (g)	Weight (g) at 1 month	Weight gain (g) per 30 days	Weight gain rate (g/day)
32	1818	3200	1382	46.1
33	1450	3600	2150	71.7
37	2877	4032	1155	38.5
40	3362	4510	1148	38.3

¹Thompson and Cohle [32].

6.2 Nadine's organ's weights

Nadine's organs' weights presented in Table 3 show that several of her organs weighed significantly less than the organs of a comparable premature infant who died at one month of age. These data also indicate that Nadine suffered from chronic illness and she did not eat well.

Table 3. Comparison between Nadine's organ weights and the organs of a premature infant died at one month of age

Organ Type	(1) Nadine's Organ's weight (g)	(2) Organ's weight (g) of one-month-old premature infant ¹	(1) as % of (2)
Brain	370	420	88
Heart	14	20	70
Right lung	40	48	79
Left Lung	38	38	100
Liver	106	150	71
Spleen	12	12	100
Kidneys	29	36	78

¹This infant was also born at 33 weeks of gestation similar to Nadine and died at one month of age. The infant's weights at birth and at one month of age were 1450 g and 3800 g, respectively [32].

7. The likely causes of the intracranial bleeding observed in Nadine's case

My review of the medical data indicates that the primary cause of the bleeding in Nadine's case is vitamin K deficiency. The intracranial bleeding observed in Nadine's case was fresh and old. Microscopic examination of H & E stained tissue sections of the bleeding areas in the brain and the membranes revealed the presence of abundant pigment-loaded macrophages and hemosiderin and iron. In addition, gliosis was observed in Nadine's brain as described in Section 4 of this report. These data indicate that the bleeding in Nadine's case was probably started four weeks prior to her death.

Premature and full term infants who have vitamin K deficiency usually suffer from intracranial hemorrhage and bleeding in other locations. Nadine had several predisposing factors for Vitamin K deficiency. These include: (1) Nadine was treated with three courses of antibiotics during the first month of her life. Treatment of infants and older children with high therapeutic doses of antibiotics for a significant time causes vitamin K deficiency by inhibiting the growth of microflora in the intestine that synthesize vitamin K. (2) Nadine was breast-fed during her life and breast milk contains very low concentration of vitamin K. Furthermore, her mother took antibiotic for 10 days during the time when she breast-fed Nadine. (3) Nadine was sick during her life and her illness caused her to eat less. Nadine's weight gain rate was 58% below the normal rate for her age. (4) Nadine suffered from hyperbilirubinemia and a high bilirubin level may induce vitamin K deficiency by causing cholectasis.

Below are medical studies that explain and describe the physiological roles of vitamin K in the blood coagulation process; symptoms and lesions of vitamin K deficiency in children; and the predisposing factors that lead to vitamin K deficiency and intracranial bleeding in children.

7.1 Physiological roles of vitamin K and biomarkers of vitamin K deficiency

Vitamin K controls the formation of coagulation factors II (prothrombin), VII (proconvertin), IX (Christmas factor), and X (Stuart factor) in the liver. Other coagulation factors that depend on vitamin K are proteins C, S, and Z. Furthermore; two bone matrix proteins necessary for normal bone metabolism are vitamin K-dependent. All of these vitamin K-dependent proteins contain the amino acid γ -carboxyglutamic acid and the carboxyl groups of the glutamic acid residues that provide the vitamin-K-dependent proteins with characteristic calcium and phospholipid binding properties [33-36].

Vitamin K deficiency in people results in a depletion of liver stores of phyloquinone and a reduction in plasma level of vitamin K1. Children suffer from vitamin K deficiency have increased plasma levels of K1 epoxide and noncarboxylated protein (PIVKA) and a reduction in the levels of functioning vitamin K-dependent clotting factors. Their prothrombin time (PT) and activated partial thromboplastin time (APPT) are prolonged. When the progression of deficiency leads to abnormal clotting tests a generalized bleeding tendency occurs.

Physicians who treated Nadine in the hospital did not measure her PT and APTT or the level of noncarboxylated prothrombin (PIVKA) in her plasma. PT, APPT are considered important indicators for vitamin K deficiency. PT and APTT are prolonged in infants suffered from vitamin K deficiency and their values returned to normal following the administration of vitamin K. Increased level of PIVKA-II in serum is also considered as an indicator of vitamin K deficiency [33-40].

For example, Bor *et al.* measured PT and APPT in fifteen infants who developed bleeding as a result of vitamin K deficiency. The age (mean \pm SD) at onset of symptoms was 62.4 \pm 33.9 days. PT and APTT were found to be highly elevated and were reduced sharply in a few hours following the administration of vitamin K1. Before administration of vitamin K, PT was 76.1 \pm 43.0 s and PTT was 123.4 \pm 68.8 s. Six to 12 hours after administration of vitamin K, PT and APTT were reduced to 15.6 s and 33.4s, respectively [37].

Further more, Choo *et al.* conducted a retrospective study of 42 newborns who were admitted to the hospital for spontaneous bleeding and prolonged prothrombin and partial thromboplastin times. None of the infants had bleeding due to inherited coagulopathy or disseminated intravascular coagulation. All the infants had prolonged prothrombin and partial thromboplastin times which were corrected by administration of vitamin K at an initial dose of 1-5 mg/daily [38].

A healthy-appearing infant with hemorrhaging should be suspected of having vitamin K deficiency. The diagnosis of vitamin K deficiency should be suspected in nearly all infants with abnormal findings on screening coagulation studies. The final diagnostic confirmation of vitamin K deficiency is a rapid, therapeutic response to vitamin K1 administration [33, 32, 37].

7.2 Bleeding and symptoms observed in infants suffered from vitamin K deficiency

Infants who develop vitamin K deficiency usually suffer from symptoms and intracranial hemorrhage similar to those

observed in Nadine's case. The followings are clinical studies that list the symptoms and bleeding locations in infants who suffered from vitamin K deficiency:

1. Chaou *et al.* reported late-onset intracranial hemorrhage related to vitamin K deficiency in 32 breast-fed infants (1/2 to 6 months of age). Computerized tomography showed mild to severe intracranial hemorrhage. Most (90.6%) had subarachnoid hemorrhage, either alone or in combination with subdural hemorrhage (37.5%), parenchymal hemorrhage (31.3%), or intraventricular hemorrhage (12.5%) [41].

2. Choo *et al.* conducted a retrospective study of 42 newborns who were admitted to the hospital for spontaneous bleeding and prolonged prothrombin and partial thromboplastin times. None of the infants had bleeding due to inherited coagulopathy or disseminated intravascular coagulation. The six commonest presenting clinical features were pallor, jaundice, umbilical cord bleeding, tense fontanelle, convulsions and hepatomegaly. Anemia was common, especially in cases with massive intracranial bleed. Subdural hemorrhage was the commonest form of intracranial haemorrhage, followed by subarachnoid haemorrhage. The overall case fatality rate was 14%. All infants had prolonged prothrombin and partial thromboplastin times, which were corrected by administration of vitamin K at an initial dose of 1-5 mg/daily [38].

3. Aydinli *et al.* conducted a retrospective study included 11 babies between 30 and 119 days of age, who developed bleeding due to vitamin K deficiency. The localizations of the intracranial hemorrhage were as follows: intracerebral (91%), subarachnoid (46%), subdural (27%), and intraventricular (27%). The presenting complaints were seizures (91%), drowsiness (82%), poor sucking (64%), vomiting (46%), fever (46%), pallor (46%), acute diarrhea (27%), irritability and high-pitched cry (18%). On examination, tense or bulging fontanelle (73%), anisocoria (36%), weak neonatal reflexes (18%), cyanoses (18%) were the most frequent findings [42].

4. Bor *et al.* evaluated 15 infants who developed bleeding in the nervous system and other locations. The age (mean \pm SD) at onset of symptoms was 62.4 \pm 33.9 days. Neurologic, gastrointestinal and skin hemorrhagic findings were found in 11 (73%), three (20%) and three patients (20%), respectively. There were both neurologic and skin bleeding symptoms in two patients. Signs and symptoms of the patients were convulsions (47%), feeding intolerance and poor sucking (47%), irritability (33%) and pallor (20%).

In physical examination; there was bulging or full fontanel in 10 patients (67%), diminished or absent neonatal reflexes in nine patients (60%) and ecchymosis in three patients (20%). Before administration of vitamin K, prothrombin time (PT) was 76.1 \pm 43.0 s and partial thromboplastin time (PTT) was 123.4 \pm 68.8 s. Six to 12 h after administration of vitamin K, PT was 15.6 \pm 1.8 s and PTT was 33.4 \pm 1.0 s. The mortality in the present study was 33% [37].

5. Hanawa *et al.* reported 543 cases of vitamin K deficiency occurring in infants over 2 weeks of age. They divided these

patients to three groups based on the causes that led to vitamin K deficiency in these infants. The first group consisted of 427 infants who showed no obvious reasons for vitamin K deficiency. In this group, 387 cases (90.0%) were entirely breast-fed and intracranial hemorrhage was observed in 353 cases (82.7%) of this group. 269 cases (63.0%) developed bleeding episodes between the 1st and 2nd months of age. The second group included 57 cases who had bleeding episodes due to vitamin K deficiency associated with obvious hepatobiliary lesions, chronic diarrhea, long-term antibiotic therapy, etc. The third group, consisting of 59 cases in which a hemorrhagic tendency, without any obvious clinical hemorrhage, was discovered by Normotest, at the time of mass screening [43].

6. Nishio *et al.* examined 84 cases of intracranial hemorrhage due to vitamin K deficiency from literatures, and they were all identified for the hemorrhage sites by CT scan. Subarachnoid hemorrhage was in 72 cases (85.7%), subdural hemorrhage was in 41 cases (48.8%), intracerebral hematomas was in 36 cases (42.9%) and intraventricular hemorrhage was in 9 cases (10.7%) [44].

7.3 Requirement of vitamin K in breast-fed infants and ill children

Nadine was breast-fed during her short life. Vitamin K deficiency remains a worldwide problem in breast-fed infants as shown in the studies described below. The transfer of vitamin K from mother through placenta to infant is very poor and vitamin K concentrations in human milk are very low. The daily requirement for vitamin K in an infant is about 1 µg/kg and breast milk contains 1 to 3 µg vitamin K/L.

In addition, the neonatal liver is immature with respect to prothrombin synthesis and the neonatal gut is sterile during the first few days of life. Thus, the newborn infant has undetectable vitamin K serum levels in the blood with abnormal amounts of the coagulation proteins and undercarboxylated prothrombin. Plasma phyloquinone concentrations in the infants fed human milk remained extremely low (mean less than 0.25 ng/mL) throughout the first 6 months of life [33, 45, 46].

Infant usually is injected with one injection of 1 mg vitamin K (IM) at birth and Nadine's record did not state that she was given vitamin K following birth. The clinical studies described below show that even injecting 1 mg of vitamin K (IM) to the infant following birth did not prevent bleeding in breast-fed babies resulting from vitamin K deficiency [34, 47, 48]. Nadine's medical record shows that she was exclusively breastfed during her life and she was treated with three courses of antibiotics that reduced the synthesis of vitamin K by bacteria in Nadine's intestine. In addition, she suffered from illnesses that led to reduction in food intake and absorption of nutrient from her GI tract.

1. Cornelissen *et al.* conducted prospective clinical trials of different methods of vitamin K prophylaxis to establish recommendations for the prevention of vitamin K deficiency in healthy breastfed infants. In this study, breast-fed infants at the ages of 2, 4, 8 and 12 weeks were treated with either once 1 mg vitamin K1 orally (n = 165) or intramuscularly (n = 166), or

weekly 1 mg orally (n = 48), or daily 25 micrograms orally (n = 58). The two single administrations of 1 mg were found to be insufficient to prevent the appearance of PIVKA-II and vitamin K deficiency after the age of 1 month. When vitamin K was administered at 1 mg per week or 0.025 mg per day, significantly higher concentrations of vitamin K1 were found and no PIVKA-II was detectable [47].

2. Widdershoven *et al.* treated thirteen breast-fed infants with 1 mg vitamin K1 (IM) at birth. The levels of vitamin K in plasma reached as high as 32711 ± 25375 pg/mL shortly after birth. However, at one month of age the vitamin K1 levels in the plasma of these infants were down to 698 ± 536 (n= 9) and this is the range found in breast-fed infants not receiving vitamin K prophylaxis [34].

3. Verity *et al.* presented three infants with the late-onset form of Hemorrhagic Disease of the Newborn (4, 6, and 7 weeks after birth) who had received of 1 mg of vitamin K at birth [48].

7.4 Antibiotics cause vitamin K deficiency in infants and older children

Vitamin K is essential because the 1, 4 naphthoquinone nucleus cannot be synthesized by the body. However, bacteria in the intestinal tract synthesize vitamin K and can supply part of the vitamin K requirement. Treatment of infants and older children with high therapeutic doses of antibiotics for a significant time causes vitamin K deficiency. Antibiotics inhibit the growth of microflora in the intestine that synthesizes vitamin K. Vitamin K deficiency is known to cause coagulopathy, intracranial bleeding and bleeding in other locations in infants and older children on prolonged antibiotics [43, 44, 49-56].

Nadine was treated with antibiotics for a few days after birth and during her hospitalization on September 2-7, 2004. She was treated with three courses of antibiotics during the first month of her life as shown in Table 4. Furthermore, Nadine's mother took antibiotic for 10 days after giving birth and Nadine was breast-fed during this period. Treatment of mother with antibiotics can cause reduction in concentration of vitamin K in breast-milk. In addition, antibiotics excreted in the breast-milk and ingested by the infants can cause diarrhea and vitamin K deficiency in infants. I evaluated a case of 3-month-old infant who developed diarrhea and vitamin K deficiency. His mother breast-fed him during her treatment with antibiotics [57].

Table 4. Treatment of baby Nadine and her mother with antibiotics

Individual treated	Duration of treatment	Antibiotic type & dose	Reason for Treatment
Nadine's mother	10 days Aug. 9-18, 2004	Standard dose Name not given	Infection with Streptococcus
Nadine	Few days Started Aug. 8, 2004	Standard dose Name not given	Suspected infection
Nadine	5 days Sept. 2-7, 2004	260 mg of Benzylpenicillin & 65 mg of Nebcina (Tobramycin)/day	Suspected infection

The followings are clinical studies show that treatment of infants and older children with antibiotics caused vitamin K deficiency and intracranial bleeding:

1. Demiroren *et al.* evaluated the medical records of 19 infants (13 male and 6 female) with a diagnosis of intracranial hemorrhage (ICH) due to vitamin K deficiency after the newborn period. The localizations of the ICHs were as follows: parenchymal (47%), subarachnoid (47%), subdural (42%), and intraventricular (26%). The most frequent presenting complaints were convulsion (58%), vomiting (47%), and irritability (47%). The most frequent examination findings were coma (74%), fontanel bulging (68%), and absence of pupil reaction (42%). The mean age at onset of the symptoms was 49 +/- 18 days (range: 30-105 days). Mortality was observed in 6 (32%) infants. All babies were breast-fed, born at term of healthy mothers [49].

Before the onset of the symptoms, four infants had used antibiotics for respiratory infection, one infant suffered from diarrhea, and one infant had a mild hepatic dysfunction. The authors recommended giving vitamin K to breast-fed infants up to the age of six months and to babies who are having liver problem, diarrhea, and/or receiving antibiotic treatment [49].

2. Bhat and Deshmukh conducted a prospective non-randomized study on children on antibiotic therapy at a tertiary care hospital. Children in the 1 month-1 year age group developed significant coagulopathy as compared to other age groups. Coagulation abnormalities were also seen to be more in children with greater grades of malnutrition, on a more prolonged course of antibiotics and in children who were critically ill in intensive care. Inhibition of intestinal microorganisms by antibiotics was thought to be a likely explanation of this phenomenon. They suggested vitamin K prophylaxis in severely ill patients, on extended periods of antibiotics and inadequate diet to prevent morbidity and mortality [50].

3. Sunakawa *et al.* evaluated infants infected with group B Streptococcus and treated with the antibacterial ceftriaxone (CTRX). Observed adverse reactions included diarrhea and vomiting. An examination for the vitamin K deficiency in 11 cases found a prolongation of prothrombin time (PT) in 3 cases and protein induced by vitamin K absence (PIVKA) II positive in 2 cases [51].

4. Kobayashi *et al.* reported a case of a male infant with congenital tuberculosis who developed cerebral hemorrhage associated with vitamin K deficiency during treatment with isoniazid and rifampin. Despite an absence of risk factors for vitamin K deficiency, the severe hemorrhagic disorder occurred at 4 months of age [52].

5. Suzuki *et al.* reported a case of a 3-month-old male infant with intracranial hemorrhage attributable to a vitamin K deficiency. Vitamin K2 was administered orally at birth and At 5 days and one month of age. Oral antibiotics were also given 2 days before the onset of bleeding. They suggested that vitamin K prophylaxis to be given especially to breast-fed infants and for those undergoing antibiotic therapy [53].

6. Nishio *et al.* evaluated a 60-day-old male infant with spontaneous intracerebral hematomas due to vitamin K deficiency. CT scan was showed four intracerebral hematomas. He was breast-fed. He was also received oral antibiotic agent for diarrhea and fever. Three days later he developed petechial hemorrhage, vomiting and twitching, and became drowsy. The blood studies showed anemia. He was administered of vitamin K immediately [44].

7. Naveh *et al.* evaluated a breast-fed 25-day-old infant who was hospitalized because of swelling and tenderness of the left leg. Radiographic examination showed widening of the left articular hip joint space. On the day of admission, a presumptive diagnosis of septic arthritis was entertained, and antibiotic therapy was instituted. Following profuse bleeding from sites of skin punctures, coagulation studies were performed. Prothrombin time and partial thromboplastin time were prolonged. Administration of phyloquinone (vitamin K1) resulted in rapid normalization of coagulation [54].

8. Sunakawa *et al.* found that the incidences of diarrhea after administering oral antibiotics in children were high for amoxicillin and amoxicillin + clavulanic acid. In some patients with depressed immunity, such as leukemic patients and neonates, decreases in intestinal bacteria after doses of antibiotics led to increases in pathogenic bacteria. They invaded the circulating blood, leading to septicemia. Septicemia originating in the intestinal tract was frequently associated with the development of vitamin K deficiency. Besides changes in the intestinal flora, a decrease in oral food intake and the presence of a methylthio-tetrazole group in the structure of the administered antibiotics were also found to play a crucial role in causing vitamin K deficiency [55].

9. de Montalembert evaluated the medical records of 43 cytic fibrosis patients and found a significant correlation between PIVKA-II concentrations and the administration of antibiotics in these patients [56].

7.5 High bilirubin level may induce vitamin K deficiency

There is clinical evidence that showed hyperbilirubinemia caused some degree of vitamin K deficiency in babies due to mild cholestasis. For example, Tiker *et al.* evaluated 77 healthy, term, breast-fed infants with jaundice and 56 age-matched, healthy, term, non-jaundiced controls. The 133 babies were divided into three subgroups according to their total bilirubin levels [group I (controls) < 50 micromol/L, group II = 50-100 micromol/L (29-58 mg/L), and group III > 100 micromol/L], and the findings for prothrombin time (PT), activated partial thromboplastin (APTT) time, and international normalization ratio were compared.

A significant positive correlation between bilirubin levels and PT and APTT suggest that a higher bilirubin load to the liver may cause some degree of vitamin K deficiency due to mild cholestasis [58]. Nadine's bilirubin level on September 2, 2004 was 200 mg/L which was 3-6 times the levels of bilirubin measured in the serum of the children monitored in this study cited above.

8. Medical data that argue against the validity of the medical examiner's opinions given in Nadine's case

Dr. Mario Verdicchio performed the autopsy on Nadine's body on September 17, 2004. His examination of Nadine's body and organs at autopsy and bone x-ray revealed no evidence of injuries caused by trauma [2]. However, he alleged that she died as a result of shaking-force occurred on September 16, 2004. He based his allegation on the finding of old and new bleeding in her brain and the membranes covering the brain during the autopsy. I presented his findings in this case in Section 3 of this report.

Below is a list of clinical data and medical facts that show Verdicchio did not perform the needed clinical tests or do differential diagnosis to rule out vitamin K deficiency, hemolytic anemia, infections, and development problems as causes for Nadine's illness and death.

1. Verdicchio stated that subdural bleeding and the bleeding in the brain (new and old) was caused by blunt shaking force and the new bleeding have appeared in direct conjunction with death. Verdicchio alleged that the fresh and the old bleeding observed in Nadine's brain and the subdural space was caused by Shaking-force without considering vitamin K deficiency in this case.

Premature and full term infants who have suffered from vitamin K deficiency also developed intracranial hemorrhage and bleeding in other locations as I explained in Section 7 of this report. Nadine had several predisposing factors for vitamin K deficiency. These include: (a) She was treated with three courses of antibiotics during the first month of her life. Treatment of infants and older children with high therapeutic doses of antibiotics for a significant time causes vitamin K deficiency by inhibiting the growth of microflora in the intestine that synthesize vitamin K. (b) Nadine was breast-fed during her life and breast milk contains very low concentration of vitamin K. Furthermore, her mother took antibiotic for 10 days during the time when she breast-fed Nadine. (c) Nadine was sick during her life and her illness caused her to eat less. Nadine's weight gain rate is 58% below the normal gain rate for her age. d) Nadine suffered from hyperbilirubinemia and a high bilirubin level can induce vitamin K deficiency by causing cholestasis. These factors also led to vitamin K deficiency even in babies who received 1 mg of vitamin K by intramuscularly following birth.

Furthermore, Verdicchio did not take blood sample prior to autopsy to measure the levels of vitamin K1 and noncarboxylated protein (PIVKA) in Nadine's blood or to measure prothrombin time (PT), and activated partial thromboplastin time (APPT) to rule out vitamin K deficiency. Vitamin K deficiency in children results in a depletion of liver stores of phylloquinone and a reduction in plasma level of vitamin K1. Children suffered from vitamin K deficiency had increased plasma levels of K1 epoxide and noncarboxylated protein (PIVKA) and a reduction in the levels of functioning vitamin K-dependent clotting factors. Their prothrombin time (PT) and activated partial thromboplastin time (APPT) are prolonged. Also, he did not do blood test to check for white blood cells and differential counts to rule out sepsis.

2. Verdicchio stated that Nadine's older injuries (old blood, hemosidrin, and gliosis) have appeared at least one week prior to death, which also caused by similar trauma. We can state that the old bleeding was at least one week old but cannot say this as far as the gliosis is concerned. The clinical data presented in Section 4 of this report show that bleeding in the brain caused gliosis and experimental studies showed that gliosis was observed one week following the injection of the blood into the brain and lasted for at least three weeks.

These data indicate that the gliosis in Nadine's brain was probably started four weeks prior to her death. Furthermore, unconjugated bilirubin (UCB) can cross the brain barrier and causes brain damage (encephalopathy) and gliosis. Nadine suffered from hyperbilirubinemia following her birth on August 7, 2004 and during her hospitalization in September 2-7, 2004.

3. Verdicchio alleged that inhalation of the stomach contents was resulted from injuries caused by shaking force. I believe that the likely causes for finding stomach contents in Nadine's lungs are her neurological problems caused by the bleeding in the brain.

4. Verdicchio stated that the findings speak strongly for that death was caused by injuries and the collected picture speaks strongly for death being caused by another person. The medical evidence cited above and presented in this report disagree with Verdicchio's statements. Nadine's illness and death were caused by health problems and adverse reactions to antibiotics. These include jaundice, hemolytic anemia, infection, vitamin K deficiency, and development problem. Verdicchio did not do differential diagnosis in this case or perform the required clinical tests to rule out the involvement of vitamin K deficiency, hemolytic anemia, jaundice, and sepsis in this case.

For example, Nadine suffered from hemolytic jaundice on September 2, 2004 and her plasma bilirubin level was 200 mg/L. In addition, Nadine's low weight gain indicates that she suffered from serious health problem and she was susceptible to infection. She gained only 625 g during her 40 days of life and her weight gain rate was 15.6 grams per day. She expected to gain at least 38 grams per day based on the average weight gains for infants born at 32 to 40 weeks of gestation. Nadine's weight gain rate was 58% below the weight gain of infant in her age.

9. Clinical data that argue against the validity of Olof Flodmark's diagnosis and opinions given in Nadine's case

Dr. Olof Flodmark is a physician specialized in neuro-radiology. He was asked to review Nadine's case (case # B 1402-05 R 12) and to give his opinions concerning the possible causes of Nadine's illness, bleeding, and death. He wrote a report on July 6, 2005 describing his diagnosis and opinions in Nadine's case [59]. He stated the followings:

1. The direct cause of death in Nadine's case is probably breathing-cessation and unconsciousness caused by an acute brain injury as a result of 'shaking-force occurred on September 16, 2004.

2. The brain swelling found in Nadine's case during the autopsy on September 17, 2004 was developed rapidly on September 16th due to lack of oxygen caused by the cessation of breathing.
3. The fresh intracranial bleeding observed during the autopsy in Nadine's case caused by shaking-force occurred on September 16, 2004.
4. The possible cause of Nadine's symptoms (apnea, sluggishness and slow response, hypotonicity, and yellow skin) displayed on the 1st and 2nd September 2004 was Shaking force occurred on the 1st of September and then again on the 2nd of September.
5. It is fully possible that the old intracranial bleeding observed by the medical examiner during the autopsy in Nadine's case was caused by shaking-force occurred on the 1st of September and then again on the 2nd of September.

The clinical data presented in this report (Sections 2-8) clearly show that Flodmark's assumptions stated above are not supported by medical facts. Below is a list of medical facts that argues against the validity of Flodmark's theories.

1. Flodmark assumed that the cause of the fresh and the old intracranial bleeding observed in Nadine's case was shaking-force without considering vitamin K deficiency in this case. Premature and full term infants who have suffered from vitamin K deficiency also developed intracranial hemorrhage and bleeding in other locations. I presented clinical studies on vitamin K deficiency and bleeding in Section 7 of this report.

Nadine had several predisposing factors for vitamin K deficiency. These include: (a) Nadine was treated with three courses of antibiotics during the first month of her life. Treatment of infants and older children with high therapeutic doses of antibiotics for a significant time causes vitamin K deficiency by inhibiting the growth of microflora in the intestine that synthesize vitamin K. (b) Nadine was breast-fed during her life and breast milk contains very low concentration of vitamin K. Furthermore, her mother took antibiotic for 10 days during the time when she breast-fed Nadine. (c) Nadine was sick during her life and her illness caused her to eat less. Nadine's weight gain rate was 58% below normal for her age. (d) Nadine suffered from hyperbilirubinemia and a high bilirubin level may induce vitamin K deficiency. These factors can lead to vitamin K deficiency even in babies who received 1 mg of vitamin K by intramuscularly following birth.

Furthermore, the levels of vitamin K1 and noncarboxylated protein (PIVKA) in Nadine's plasma, prothrombin time (PT), and activated partial thromboplastin time (APPT) were not measured to rule out vitamin K deficiency. Vitamin K deficiency in children results in a depletion of liver stores of phyloquinone and a reduction in plasma level of vitamin K1. Children suffer from vitamin K deficiency have increased plasma levels of K1 epoxide and noncarboxylated protein (PIVKA) and a reduction in the levels of functioning vitamin K-dependent clotting factors. Their prothrombin time (PT) and activated partial thromboplastin time (APPT) are prolonged.

2. Flodmark assumed that the brain swelling in Nadine's case observed during the autopsy occurred rapidly due to lack of oxygen resulted from brain injury caused by shaking-force occurred on September 16, 2004. The clinical data presented in Section 4 of this report show that bleeding in the brain causes inflammation and edema and the fluid in the brain was increased with time up to 72 hours post bleeding. Fresh and old bleeding was found in Nadine's brain and Flodmark did not consider the bleeding as the cause of the brain edema in this case.

3. Flodmark stated that it is fully possible that the old intracranial bleeding observed during the autopsy and Nadine's illness developed on September 2, 2004 were caused by shaking-force occurred on the 1st of September and then again on the 2nd of September.

The following clinical data clearly disagree with Flodmark's assumptions. (a) Nadine suffered from hemolytic jaundice on September 2, 2004 and her plasma bilirubin level was 200 mg/L. Hemolytic anemia and jaundice can cause Nadine's symptoms observed on September 2nd. (b) Experimental studies show that the blood in the brain was converted to hemosiderin in about 5-7 days post bleeding. These medical facts invalidate Flodmark's statement that the old bleeding in Nadine's brain started 16 days prior to her death. (c) The levels of vitamin K1 and noncarboxylated protein (PIVKA) in Nadine's plasma, prothrombin time (PT), and activated partial thromboplastin time (APPT), were not measured on September 2, 2004 to rule out vitamin K deficiency in this case. (d) Nadine's low weight gain indicates that she suffered from serious health problem and she was susceptible to infection. Her weight on September 2 was 2.62 kg and she gained 385 grams during her 26 days of life. Her weight gain rate was 14.8 g/day, which is about 40% of the average normal weight gain rate for her age. She was treated with two courses of antibiotics for five days started on September 2nd.

4. Flodmark did not mention in his report that the medical examiner reported the presence of gliosis in Nadine's brain. He overlooked crucial medical information that show Nadine was bleeding chronically in the brain and the bleeding started probably four weeks prior to her death. In addition, she suffered from chronic neurological problems. The medical examiner stated that the microscopic examination of H & E stained tissue sections of Nadine's brain revealed the presence of mild to heavy reactive gliosis in the cortex. In addition the immunohistochemical staining for glial fibrillary acidic protein (GFAP) showed the gliosis was continued deeper into the underlying white substance.

The clinical data presented in Section 4 of this report show that bleeding in the brain causes gliosis. Experimental studies showed that gliosis was observed one week following the injection of the blood into the brain and lasted for at least three weeks. The bleeding in Nadine's brain was fresh and old. The old bleeding was probably one week old. These data indicate that the gliosis in Nadine's brain was probably started prior to her death. Furthermore, unconjugated bilirubin (UCB) can cross

the brain barrier and causes brain damage (encephalopathy) and gliosis. Nadine suffered from hyperbilirubinemia following her birth on August 7, 2004 and during her hospitalization in September 2–7, 2004.

10. Conclusions

My review of the clinical data in this case and the pertinent medical literature revealed the followings:

The likely cause of the fresh and old bleeding observed during the autopsy in Nadine's brain, subdural space, and under the other membranes surrounding the brain is vitamin K deficiency.

1. The bleeding probably occurred during four weeks prior to Nadine's death on September 16, 2004.

2. The likely cause of the brain edema observed in Nadine's case is the bleeding and the edema was probably formed during the 72 hours prior to Nadine's death.

3. The gliosis observed in Nadine's brain was induced by the bleeding and the gliosis was probably started four weeks prior to Nadine's death. Hyperbilirubinemia might contributed to the formation of the gliosis in this case.

4. Nadine suffered from hemolytic jaundice, infection, and neurological problems that caused her to eat less and to develop growth retardation. She gained only 625 grams during her 40 days of life (15.6 g/day) which is about 58% below the weight gain expected for an infant in her age.

5. Verdicchio's allegations that Nadine died as a result of shaking-force occurred on September 16, 2004 and she was killed by other person are medically not valid. He did not perform the needed clinical tests prior to autopsy or do differential diagnosis to rule out the involvement of vitamin K deficiency, hemolytic anemia, infections, and developmental and neurological involvement in Nadine's illness and death.

6. Flodmark's allegation that the fresh and the old intracranial bleeding observed in Nadine's case was caused by shaking-force occurred on September 1st, 2nd, and 16th is not medically valid. He did not perform differential diagnosis to rule out vitamin K deficiency, hemolytic anemia, infections, and developmental and neurological problems as causes for Nadine's illness and death. In addition, he did not consider the gliosis observed in Nadine's brain in his evaluation of this case.

In conclusion, my investigation in Nadine's case, clearly indicates that Nadine died as result of health problems and vitamin K deficiency that led to intracranial bleeding, neurological problems, and cardiac arrest. She was not injured and killed by her father, Ezbjörn Hahne, as alleged by Verdicchio and Flodmark.

References

- [1] Nadine's medical records from August 7 to September 17, 2004.
- [2] Verdicchio M. Forensic medicine report: autopsy report for Baby Nadine. *Medical Veritas* 2006 Nov.;3(2):994–6.
- [3] Mayer SA, Lignelli A, Fink ME, Kessler DB, Thomas CE, Swarup R, Van Heertum RL. Perilesional blood flow and edema formation in acute intracerebral hemorrhage: a SPECT study. *Stroke*. 1998 Sep;29(9):1791–8.
- [4] Yang GY, Betz AL, Chenevert TL, Brunberg JA, Hoff JT. Experimental intracerebral hemorrhage: relationship between brain edema, blood flow, and blood-brain barrier permeability in rats. *J. Neurosurg.* 1994 Jul;81(1):93–102.
- [5] Patel TR, Schielke GP, Hoff JT, Keep RF, Lorriss Betz A. Comparison of cerebral blood flow and injury following intracerebral and subdural hematoma in the rat. *Brain Res.* 1999 May 22;829(1-2):125–33.
- [6] Xi G, Hua Y, Bhasin RR, Ennis SR, Keep RF, Hoff JT. Mechanisms of edema formation after intracerebral hemorrhage: effects of extravasated red blood cells on blood flow and blood-brain barrier integrity. *Stroke*. 2001 Dec 1;32(12):2932–8.
- [7] Gong C, Hoff JT, Keep RF. Acute inflammatory reaction following experimental intracerebral hemorrhage in rat. *Brain Res.* 2000 Jul 14; 871(1):57–65.
- [8] *Pathologic Basis of Disease*. 3rd ed.. Robbins SL, Cortan RS, Kumar V, ed. Saunders WB Company, Philadelphia, USA, 1984.
- [9] Kowianski P, Karwacki Z, Dziewiatkowski J, Domaradzka-Pytel B, Ludkiewicz B, Wojcik S, Litwinowicz B, Narkiewicz O, Morys J. Evolution of microglial and astroglial response during experimental intracerebral haemorrhage in the rat. *Folia Neuropathol.* 2003;41(3):123–30.
- [10] Karwacki Z, Kowianski P. Apoptosis in the course of experimental intracerebral haemorrhage in the rat. *Folia Morphol (Warsz)*. 2005 Nov;64(4):248–52
- [11] Koeppen AH, Dickson AC, McEvoy JA. The cellular reactions to experimental intracerebral hemorrhage. *J Neurol Sci.* 1995 Dec; 134(Suppl):102–12.
- [12] Suchonska B, Wielgos M, Bobrowska K, Marianowski L. Concentration of bilirubin in the umbilical blood as an indicator of hyperbilirubinemia in newborns. *Ginekol Pol.* 2004 Oct;75(10):749–53.
- [13] *Neonatal-Perinatal Medicine, Volume 2, Seventh Edition, 2002.* Fanaroff AA, Martin RJ, eds. Mosby, St. Louis, Missouri.
- [14] Fernandes A, Falcao AS, Silva RF, Gordo AC, Gama MJ, Brito MA, Brites D. Inflammatory signalling pathways involved in astroglial activation by unconjugated bilirubin. *J Neurochem.* 2006 Mar;96(6):1667–79. Epub 2006 Feb 10.
- [15] Oktay R, Satar M, and Atici A. The risk of bilirubin encephalopathy in neonatal hyperbilirubinemia. *Turk J Pediatr.* 1996;38(2):199–204.
- [16] Ebbesen F, Andersson C, Verder H, Grytter C, Pedersen-Bjergaard L, Petersen JR, Schaarup J. Extreme hyperbilirubinemia in term and near-term infants in Denmark. *Acta Paediatr.* 2005 Jan;94(1):59–64.
- [17] Kumral A, Genc S, Duman N, Tatli M, Sakizli M, Ozkan H. Hyperbilirubinemic serum is cytotoxic and induces apoptosis in murine astrocytes. *Biol Neonate.* 2005;87(2):99–104. Epub 2004 Nov 9.
- [18] Gordo AC, Falcao AS, Fernandes A, Brito MA, Silva RF, Brites D. Unconjugated bilirubin activates and damages microglia. *J Neurosci Res.* 2006 Apr 12; [Epub ahead of print]
- [19] Falcao AS, Fernandes A, Brito MA, Silva RF, Brites D. Bilirubin-induced inflammatory response, glutamate release, and cell death in rat cortical astrocytes are enhanced in younger cells. *Neurobiol Dis.* 2005 Nov;20(2):199–206.
- [20] Andre M, Eriksson M, Molstad S, Stalsbylundborg C, Jacobsson A, Odenholt I. Swedish Study Group on Antibiotic Use. The management of infections in children in general practice in Sweden: a repeated 1-week diagnosis-prescribing study in 5 counties in 2000 and 2002. *Scand J Infect Dis.* 2005;37(11-12):863–9.
- [21] Benitz WE, Han MY, Madan A, Ramachandra P. Serial serum C-reactive protein levels in the diagnosis of neonatal infection. *Pediatrics.* 1998 Oct;102(4):E41.
- [22] Ehl S, Gering B, Bartmann P, Hogel J, Pohlandt F. C-reactive protein is a useful marker for guiding duration of antibiotic therapy in suspected neonatal bacterial infection. *Pediatrics.* 1997 Feb;99(2):216–21.

- [23] Jankovic B, Pasic S, Markovic M, Veljkovic D, Milicic M. C-reactive protein concentrations during initial (empiric) treatment of neonatal sepsis. *Srp Arh Celok Lek*. 2001 May-Jun;129(Suppl 1):17–22.
- [24] Isaacs D, North J, Lindsell D, Wilkinson AR. Serum acute phase reactants in necrotizing enterocolitis. *Acta Paediatr Scand*. 1987 Nov;76(6):923–7.
- [25] Nuntnarumit P, Pinkaew O, Kitiwanwanich S. Predictive values of serial C-reactive protein in neonatal sepsis. *J Med Assoc Thai*. 2002 Nov;85 Suppl 4:S1151–8.
- [26] Philip AG, Mills PC. Use of C-reactive protein in minimizing antibiotic exposure: experience with infants initially admitted to a well-baby nursery. *Pediatrics*. 2000 Jul;106(1):E4.
- [27] Pourcyrus M, Bada HS, Korones SB, Baselski V, Wong SP. Significance of serial C-reactive protein responses in neonatal infection and other disorders. *Pediatrics*. 1993 Sep;92(3):431–5.
- [28] Pourcyrus M, Korones SB, Yang W, Boulden TF, Bada HS. C-reactive protein in the diagnosis, management, and prognosis of neonatal necrotizing enterocolitis. *Pediatrics*. 2005 Nov;116(5):1064–9.
- [29] Romagnoli C, Frezza S, Cingolani A, De Luca A, Puopolo M, De Carolis MP, Vento G, Antinori A, Tortorolo G. Plasma levels of interleukin-6 and interleukin-10 in preterm neonates evaluated for sepsis. *Eur J Pediatr*. 2001 Jun;160(6):345–50.
- [30] Lannergard A, Friman G, Ewald U, Lind L, Larsson A. Serum amyloid A (SAA) protein and high-sensitivity C-reactive protein (hsCRP) in healthy newborn infants and healthy young through elderly adults. *Acta Paediatr*. 2005 Sep;94(9):1198–202.
- [31] Tarcan A, Tiker F, Vatandas NS, Haberal A, Gurakan B. Weight loss and hypernatremia in breast-fed babies: frequency in neonates with non-hemolytic jaundice. *J Paediatr Child Health*. 2005 Sep-Oct;41(9-10):484–7.
- [32] Thompson WS, Cohle SD. Fifteen-year retrospective study of infant organ weights and revision of standard weight tables. *J Forensic Sci*. 2004 May;49(3):575–85.
- [33] The Merck Manual of Diagnosis and Therapy. Editors Beets MH and Berkow R, 17th ed., 1999. Published by Merck Research Laboratories, Whitehouse Station, N.J.
- [34] Widdershoven J, Labert W, Motohara K, *et al*. Plasma concentrations of vitamin K1 and PIVKA-II in bottle-fed and breast-fed infants with and without vitamin K prophylaxis at birth. *European Journal of Pediatrics*. 1988;148:139–42.
- [35] Sutor AH, von Kries R, Cornelissen EA, McNinch AW, Andrew M. Vitamin K deficiency bleeding (VKDB) in infancy. ISTH Pediatric/Perinatal Subcommittee. International Society on Thrombosis and Haemostasis. *Thromb Haemost*. 1999;81(3):456–61.
- [36] Hathaway WE. Vitamin K deficiency. *Southeast Asian J Trop Med Public Health*. 1993;24(Suppl. 1):5–9.
- [37] Bor O, Akgun N, Yakut A, Sarhus F, Kose S. Late hemorrhagic disease of the newborn. *Pediatr Int* 2000;42(1):64–6.
- [38] Choo KE, Tan KK, Chuah SP, Ariffin WA, Gururaj A. Haemorrhagic disease in newborn and older infants: a study in hospitalized children in Kelantan, Malaysia. *Ann Trop Paediatr*. 1994;14(3):231–7.
- [39] Kumar R, Marwaha N, Marwaha RK, Garewal G. Vitamin K deficiency in diarrhoea. *Indian J Pediatr* 2001;68(3):235–8.
- [40] Sutor AH. Vitamin K deficiency bleeding in infants and children. *Semin Thromb Hemost*. 1995;21(3):317–29.
- [41] Chaou WT, Chou ML, Eitzman DV. Intracranial hemorrhage and vitamin K deficiency in early infancy. *J Pediatr*. 1984;105(6):880–4.
- [42] Aydinli N, Citak A, Caliskan M, Karabocuoglu M, Baysal S, Ozmen M. Vitamin K deficiency--late onset intracranial haemorrhage. *Eur J Paediatr Neurol*. 1998;2(4):199–203.
- [43] Hanawa Y, Maki M, Murata B, Matsuyama E, Yamamoto Y, Nagao T, Yamada K, Ikeda I, Terao T, Mikami S, *et al*. The second nation-wide survey in Japan of vitamin K deficiency in infancy. *Eur J Pediatr* 1998;147(5):472–7.
- [44] Nishio T, Nohara R, Aoki S, Sai HS, Izumi H, Miyoshi K, Morikawa Y, Mizuta R. Intracranial hemorrhage in infancy due to vitamin K deficiency: report of a case with multiple intracerebral hematomas with ring-like high density figures. *No To Shinkei*. 1987 Jan;39(1):65–70.
- [45] Greer FR. Vitamin K status of lactating mothers and their infants. *Acta Paediatr Suppl*. 1999; 88(430):95–103.
- [46] Greer FR, Marshall S, Cherry J, Suttie JW. Vitamin K status of lactating mothers, human milk, and breast-feeding infants. *Pediatrics*. 1991;88(4):751–6.
- [47] Cornelissen EA, Monnens LA. Evaluation of various forms of vitamin-K prophylaxis in breast-fed infants. *Ned Tijdschr Geneesk* 137(43):2205–8, 1993.
- [48] Verity CM, Carswell F, Scott GL. Vitamin K deficiency causing infantile intracranial haemorrhage after the neonatal period. *Lancet I*: 1439, 1983.
- [49] Demiroren K, Yavuz H, Cam L. Intracranial hemorrhage due to vitamin K deficiency after the newborn period. *Pediatr Hematol Oncol*. 2004 Oct - Nov;21(7):585–92.
- [50] Bhat RV, Deshmukh CT. A study of Vitamin K status in children on prolonged antibiotic therapy. *Indian Pediatr*. 2003 Jan;40(1):36–40.
- [51] Sunakawa K, Ishizuka Y, Saito N, Kawai N, Akita H, Iwata S, Sato Y. Fundamental and clinical evaluations of ceftriaxone in neonates. *Jpn J Antibiot*. 1988 Feb;41(2):133–43.
- [52] Kobayashi K, Haruta T, Maeda H, Kubota M, Nishio T. Cerebral hemorrhage associated with vitamin K deficiency in congenital tuberculosis treated with isoniazid and rifampin. *Pediatr Infect Dis J*. 2002 Nov;21(11):1088–90.
- [53] Suzuki K, Fukushima T, Meguro K, Aoki T, Kamezaki T, Saitoh H, Enomoto T, Nose T. Intracranial hemorrhage in an infant owing to vitamin K deficiency despite prophylaxis. *Childs Nerv Syst*. 1999 Jul;15(6-7):292–4.
- [54] Naveh Y, Berant M, Bialik V. Vitamin K deficiency presenting with hemarthrosis. *J Pediatr Orthop*. 1984 Sep;4(5):630–2.
- [55] Sunakawa K, Akita H, Iwata S, Sato Y. Clinical superinfection and its attendant symptomatic changes in pediatrics. *Infection*. 1985;13 Suppl 1:S103–11.
- [56] de Montalembert M, Lenoir G, Saint-Raymond A, Rey J, Lefrere JJ. Increased PIVKA-II concentrations in patients with cystic fibrosis. *J Clin Pathol*. 1992 Feb;45(2):180–1.
- [57] Al-Bayati MA. Analysis of Causes That Led to Baby Lucas Alejandro Mullenax-Mendez's Cardiac Arrest and Death in August-September of 2002. *Medical Veritas*, 2004 Apr.;1(1):45–63.
- [58] Tiker F, Gurakan B, Tarcan A. Relationship between serum bilirubin and coagulation test results in 1-month-old infants. *Indian J Pediatr*. 2005 Mar;72(3):205–7.
- [59] Flodmark O. Expert Testimony regarding Case B 1402-05 R 12 given by Olaf Flodmark on July 6, 2006. *Medical Veritas*, 2006 Nov.;3(2):991–3.

Figure 1. Shows the distribution of the fresh and old bleeding in Nadine's brain observed at the time of autopsy. (Courtesy of the Gothenburg office of the National Board of Forensic Medicine, Rättsmedicinalverket, <http://www.rmv.se/>)

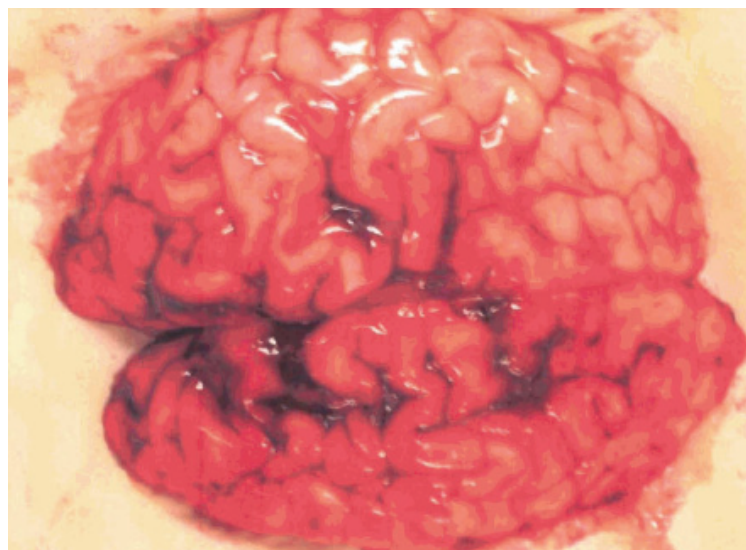


Figure 2. Shows the intensity and distribution of the old bleeding in Nadine’s brain (top and bottom views) observed at the time of autopsy. The microscopic examination of H & E stained tissue sections of the brain revealed the presence of mild to heavy reactive gliosis in the cortex. It indicates that the bleeding probably started at least four weeks prior to Nadine’s death. (Courtesy of the Gothenburg office of the National Board of Forensic Medicine, Rättsmedicinalverket, <http://www.rmv.se/>)

